

Analysis of causes that led to Evyn Vaughn's respiratory arrest, intracranial and retinal bleeding, and death

Mohammed Ali Al-Bayati, PhD, DABT, DABVT

Toxicologist & Pathologist

Toxi-Health International

150 Bloom Drive, Dixon, CA 95620

Email: maalbayati@toxi-health.com

Phone: +1 707 678 4484 Fax: +1 707 678 8505

Abstract

Evyn, a 14-month-old male, suffered from respiratory arrest on April 21, 2007, and was taken to the Northwest Texas Hospital. He was treated with several medications but he did not show an improvement. He was pronounced brain dead on April 22. Evyn was given heparin (3600 units IV) and his major organs were harvested for donations. At autopsy, the medical examiner (ME) observed intracranial bleeding, brain edema, widening of the sagittal suture, and optic nerve sheath hemorrhage. He alleged that Evyn's bleeding, injuries, and death were caused by blunt trauma.

Evyn's caretaker was accused of killing him. My investigation reveals that Evyn suffered from respiratory arrest as a result of bacterial infections (*Streptococcus pneumoniae* and *Haemophilus influenzae*), pneumonia, and septicemia. Bacterial infections are confirmed by bacterial blood culture, chest CT scan exam, and blood and urine analyses.

The likely causes of Evyn's bleeding were infections and septicemias, liver damage, vitamin K deficiency, and heparin. Hypoxia, medications, bleeding, and increased intracranial pressure (ICP) caused his brain edema and the widening of the sagittal suture. The 27 vaccines given to Evyn and treatment with corticosteroids caused significant health problems and immune depression that led to his infections.

The ME's allegation that Evyn's death was caused by blunt trauma is not supported by medical facts. He did not exam Evyn's lungs, heart, liver, and other infected tissues grossly and/or microscopically. In addition, he did not consider infections, septicemia, heparin, vaccines, and medications in causing Evyn's health problems and death.

© Copyright 2009, Medical Veritas International Inc. All rights reserved.

Keywords: Anemia; axonal injury; brain edema; blunt trauma; corticosteroids; *Haemophilus influenzae*; heart problem; heparin; hyperglycemia; intracranial pressure; intracranial bleeding; kidney problem; liver problem; PT; PTT; pneumonia; serum enzyme; *Streptococcus pneumoniae*; and vaccines.

1. Summary of the case and findings

Evyn Vaughn, a 14-month-old white male, suffered from respiratory arrest on April 21, 2007, and was taken to the Northwest Texas Hospital by ambulance. Evyn was sick and his mother left him at home with her friend, Michael Wayne Garrard (32-year-old white male), while she went to buy food. Michael had noticed Evyn had become limp and his eyes rolled to the back of his head while he was changing his diaper. He performed CPR and called Evyn's mother and she called 911.

The EMS brought Evyn to the ER at the Northwest Texas Hospital at 1730 on April 21, 2007. He was intubated, unconscious, and unresponsive. His blood oxygen saturation level was 86%. His heart monitor showed sinus tachycardia at 135 beats/minute. He had a temperature of 95.6°F and his abdomen was distended. His weight and length were 8.9 kg and 75 cm, respectively.

Evyn was treated with several medications but he did not show an improvement. He was pronounced brain dead at 1210 on April 22nd. However, he was maintained on life support with mechanical ventilation and endotracheal intubation until 1315 on April 23rd. Evyn was given 3600 units of heparin IV (414 IU/kg) and his organs (heart, lungs, liver, kidneys, pancreas/islet cells, and small intestine) were harvested for donation. These organs were taken one day prior to autopsy and were not examined by the medical examiner.

Dr. Thomas R. Parsons performed the autopsy on Evyn's body in Potter County, Texas on April 24, 2007 (Case # 07-0256). He observed bleeding in the soft tissues outside Evyn's

skull, widening of the sagittal suture, intracranial bleeding, severe brain edema, herniation of the brain, and optic nerve sheath hemorrhage. He also examined the H & E stained tissue sections of the brain microscopically and observed edema and hypoxic change. In addition, he found several minor bruises at various stages of healing on Evyn's body. He alleged that Evyn's bleeding, injuries, and death were caused by blunt trauma.

Michael was accused of killing Evyn, arrested, and indicted. He was charged with injury to a child and knowingly or intentionally causing serious bodily injury. Michael's mother, Michael, and Michael's defense attorney requested that I review the medical evidence in Evyn's case and provide an opinion concerning the likely causes that led to Evyn's injuries and death. I am a toxicologist and pathologist with over 20 years experience in these fields and have published over 50 articles in medical and scientific journals.

I have evaluated many cases of children who died suddenly from unexplained causes and cases of children and adults who suffered from acute and/or chronic illnesses. I was able to explain the causes of illnesses and death in these cases using differential diagnosis. I have served as an expert witness in many medical-legal cases involving children and adults.

I evaluated Evyn's medical records, autopsy report, and the articles cited in this report using differential diagnosis. I also examined the H & E stained tissue sections of Evyn's tissues and organs taken at autopsy microscopically. Approximately 300 hours were required to evaluate the medical evidence,

perform an analysis, and write this report. My investigation in this case reveals the following:

1) Evyn was suffering from bacterial infections (*Streptococcus pneumoniae* and *Haemophilus influenzae*), pneumonia, and septicemia. They caused acidosis and metabolic problems, multiorgan failure, and Evyn's respiratory arrest on April 21, 2007 as indicated by the following clinical observations:

a) A blood sample analyzed at 20 minutes following Evyn's admission to the hospital (FAH) revealed an elevated white blood cell count (WBC) of $21.8 \times 10^3/\mu\text{L}$. His white blood cell and neutrophil segmented and band counts stayed elevated at about 18 hours FAH. He was treated with antibiotics (ciprofloxacin and tobramycin) and his WBC returned to a normal level at 26 hours FAH.

b) A blood sample taken for bacterial culture at about 19 hours FAH showed a heavy growth of *S. pneumoniae* and *H. influenzae*. A Gram stain study of his sputum revealed the presence of a significant growth of Gram-positive cocci and the presence of a significant number of white blood cells. In addition, repeated blood culture performed on Evyn's blood sample taken at 26 hours FAH revealed a moderate growth of *S. pneumoniae*.

c) Evyn's chest CT scan performed at 50 minutes FAH showed diffuse abnormal density in the lungs that indicates pulmonary problem. The medical examiner (ME) did not examine Evyn's lungs to rule out pneumonia.

d) A blood analysis performed at about 2 hours FAH showed that Evyn was suffering from metabolic acidosis. He had a blood pH of 7.24, a PCO_2 level of 27.2 mm Hg, and a bicarbonate level of 11.5 mmol/L.

e) *S. pneumoniae* and *H. influenzae* are the leading causes of pneumonia and septicemia in children and should be considered in the differential diagnosis in this case. For example, Nascimento-Carvalho evaluated data from 9 studies conducted in North America and Europe dealing with the etiology of pneumonia in children. The etiology of pneumonia was established in 62% of studies (range 43%-88%) by the use of noninvasive specific methods for microbiologic diagnosis. *S. pneumoniae* and *H. influenzae* were identified in 22% and 7% of the children with pneumonia.

Furthermore, they evaluated data from 8 studies conducted in South America on the etiology of pneumonia in children. Bacteria were recovered from 56% (range 32%-68%) of severely ill children studied by lung aspirate. The most often isolated bacteria were *S. pneumoniae* (33%) and *H. influenzae* (21%).

f) Evyn was very sick during the 6 days prior to his respiratory arrest. He was not eating well, vomited a lot and had diarrhea. He had lost 200 g during the 1.5 months prior to his death on April 22, 2007. It is expected that he gains about 692 g during that period based on his previous weight gain rate of 15.72 g/day. His gain rate during the first 12.5 months of his life was 15.72 g.

g) Evyn suffered from an acute heart problem induced by septicemia. A blood analysis performed at 20 hours FAH showed that Evyn had elevated levels of creatine kinase (CK), CK-MB, lactic dehydrogenase (LDH), Myoglobin-P/S, and troponin-I. The levels of these biomarkers in serum are used to evaluate the severity of damage in cardiac muscle and cardiac dysfunction.

For example Oliveira *et al.* evaluated serum level of contractile protein troponin I (cTnI) in 218 children admitted to the hospital within the 24 hours of sepsis and septic shock. Abnormal serum levels of cTnI occurred in 10 (4.5%) patients, significantly more frequent in the septic shock group than in sepsis group (13% vs. 0.7%, respectively; $p = 0.000$). Frequency of elevated serum cTnI was significantly higher in non-survivors than in survivors (5 of 27 vs. 5 of 191, respectively; $p = 0.003$).

h) Evyn had acute liver injury. A CT scan of Evyn's abdomen performed at 50 minutes FAH showed portal edema of the liver. A blood analysis performed at 1.6 hours FAH revealed that Evyn had elevated liver enzymes levels in serum. His serum AST, ALT, and Alkaline phosphatase levels were 2-3 times the average normal level. Spapen stated that sepsis causes significant alterations in the hepatic macro- and microcirculation. Microvascular blood flow disturbances are thought to play a pivotal role in the development of sepsis-induced multiorgan failure.

i) Septicemia also caused pancreatic injury in Evyn's case. Evyn's blood glucose level was elevated at 8 hours FAH and was treated with insulin. His blood glucose reached a high level of 541 mg/dL at 43 hours FAH in spite of the treatment with high doses of insulin. His urine analysis performed at about 22 hours FAH showed a moderate amount of ketone bodies. Furthermore, a blood analysis performed at 20 FAH showed that Evyn had elevated serum amylase level of 392 IU (normal range: 98-192).

j) Urine and serum analyses indicate that Evyn suffered from kidney bacterial infections and kidney damage. His urine analysis performed at 20 hours FAH revealed the presence of albumin, red blood cells, white blood cells, and bacteria. Evyn's blood osmolality was increased significantly. He developed hypernatremia, hyperchloremia, hyperkalemia, hyperphosphatemia, and hypermagnesiumemia due to kidney problems.

2) The likely causes of Evyn's bleeding were infections, liver damage, vitamin K deficiency, and the large dose of heparin given prior to harvesting his organs as indicated by the following clinical and medical studies:

a) Most of Evyn's bleeding occurred in the hospital. A CT scan taken at 50 minutes following Evyn's admission to the hospital showed increased attenuation along the falx that raised the suspicion for the presence of subdural bleeding. However, the autopsy revealed a significant bleeding outside Evyn's skull and intracranially.

b) Septicemia is frequently accompanied by changes in the plasmatic as well as cellular coagulation systems and by microclot formation. The activation of coagulation by

endotoxin is mediated by synthesis of tissue factor by monocytes and endothelial cells. Some microorganisms have specific properties, which affect individual components of hemostasis and thus increase their virulence.

Furthermore, thrombocytopenia, thrombocytopeny and endothelial cell damage caused by a direct effect of the toxic agents contribute to the bleeding diathesis. Evyn's platelet count was within the normal range at admission but it was reduced by 40% at 26 hours FAH. It indicates that he suffered from disseminated intravascular coagulation (DIC) due to septicemia.

c) Evyn had liver problem as described above and the majority of the blood clotting factors is synthesized in the liver. Evyn's prothrombin time (PT) and international normalized ratio (INR) were elevated at 2 hours FAH and they increased by 11-13% at 18 hours FAH.

d) Evyn was sick, lost weight, and treated with antibiotics. A significant reduction of food intake occurred in serious illness and the treatment with high therapeutic doses of antibiotics for a significant time have led to vitamin K deficiency and intracranial bleeding in children. For example, Aydinli *et al.* conducted a retrospective study included 11 babies between 30 and 119 days of age, who developed bleeding due to vitamin K deficiency. The localizations of the intracranial haemorrhage were as follows: intracerebral (91%), subarachnoid (46%), subdural (27%), and intraventricular (27)

e) Heparin prevents coagulation of the blood by preventing the conversion of prothrombin to thrombin and fibrinogen to fibrin. The dose of heparin given to Evyn (3600 units) is 8.3 times the therapeutic dose given to children.

3) Evyn's brain edema, herniation, and widening of the sagittal suture developed following Evyn's admission to the hospital. A head CT scan taken at 50 minutes FAH did not show Evyn had a significant edema of the brain, herniation of the brain, or widening of the sagittal suture. These lesions were caused by hypoxia, medications, bleeding, and increased intracranial pressure (ICP).

Evyn was suffering from metabolic acidosis at the time of admission to the hospital and treated with high doses of sodium bicarbonate. He had a blood pH of 7.24 and the treatment with sodium bicarbonate IV raised his blood pH to a critically high level of 7.60. The treatment with high doses of sodium bicarbonate has caused anoxia and brain edema in children. Fauci *et al.* reported that alkalization of the blood with sodium bicarbonate increases the avidity of hemoglobin to bind oxygen, thus impairing the release of oxygen in peripheral tissues.

Kaur *et al.* studied material comprised sections from 28 brains showing evidence of cerebral hypoxia with no history of head injury to assess the possible role of hypoxia in the formation of axonal bulbs. These were subjected to microwave antigen retrieval and immunohistochemistry using monoclonal antibodies to beta amyloid precursor protein (beta APP), glial fibrillary acid protein (GFAP), and CD68-PGM1. They found positive staining for beta APP present in 12 of 28 cases of hypoxia without history of head injury. They stated that the

presence of axonal bulbs cannot necessarily be attributed to shearing forces alone.

4) The likely causes of the bruises and marks observed on Evyn's body at autopsy were septicemia, vitamin K deficiency, liver injuries, and heparin. Dr. Parsons observed 17 bruises and marks on Evyn's body. However, the treating physicians noted only 8 bruises at various stages of healing at the time of Evyn's admission to the hospital. These observations indicate that at least 9 bruises and marks developed after Evyn's admission to the hospital.

Parsons examined the H & E stained sections of Evyn's skin (back and the posterior leg) microscopically and observed various degree of extravasation of red blood cells in the subcutaneous and adipose tissues. I also examined these sections of the skin and observed fresh bleeding, less than 24 hours old (Figs. 1, 2). The autopsy was performed at 64 hours following Evyn's admission to the hospital.

5) Evyn suffered from adverse reactions to vaccines and corticosteroids, which led to his health problems, immune depression, infections, and death as indicated below.

a) Evyn received 21 vaccines between the age of 2 and 6 months and developed health problems following receiving these vaccines. The severity of his health problems increased significantly following receiving vaccines at 6 months of age. He developed bronchitis and treated with antibiotics and corticosteroids.

b) The treatment with corticosteroids led to immune suppression and increased Evyn's risk for viral, bacterial, and fungal infections. He developed viral infections, bronchitis, and thrombocytopenia. He was treated with antibiotics, antipyretics and corticosteroids. He developed fungal infection at the age of 11 months and treated with antifungal medication. His fungal infection indicates that he was suffering from a significant immune depression.

c) Evyn received six vaccines at the age of 12 months while he was suffering from immune depression. Some of these vaccines contain attenuated live viruses. Vaccines should not be given to sick children and children treated with corticosteroids.

6) Parsons' investigation in this case is incomplete and his allegation that Evyn's death was caused by blunt trauma is not supported by the clinical and medical studies described in this report. He did not exam Evyn's lung, heart, liver, and other infected tissues grossly or microscopically. In addition, he did not consider infections, septicemia, heparin, and the adverse reactions of vaccines and medications in causing Evyn's health problems and death.

2. Treatments given to Evyn's mother during labor and Evyn's health condition at birth

Evyn William Vaughn's mother (23-year-old) was admitted to the Northwest Texas Hospital on February 23, 2006 for elective pitocin induction of labor. Her sonography exam was suggestive for small for gestational age infant. Her weight prior

to pregnancy and at labor was 65.8 kg (145 lb) and 80.7 kg (178 lb), respectively. She gained 15 kg (33 lb) during her pregnancy.

She was tested positive for Group B Streptococcus and treated with penicillin. She was given epidural anesthesia and had a spontaneous vaginal delivery. Evyn was born at full term (39 5/7th weeks) on February 23, 2006. His Apgar scores were 8 and 9 at 1 and 5 minutes, respectively.

His weight at birth was 2952 g (25-50 percentile). His length and head circumference were 51.4 cm (75-90 percentile) and 33.7 cm (50 percentile), respectively [1, 2]. Evyn passed his hearing screen test and was discharged from the hospital on February 25, 2006.

He was breast-fed. His newborn screen test was performed on March 10, 2006 and revealed normal results (Table 1) [2].

Table 1. Evyn's newborn screen test

Conditions	Results
Hypothyroidism	Normal T4
Phenylketonuria	Normal Phenylalanine
Hemoglobinopathy	Normal (HB F and HbA present)
Congenital Adrenal Hyperplasia (CAH)	Normal 17-OHP for birth weight Greater than or equal to 2500 g
Galactosemia (GALT)	Normal GAL-1-P Uridyl-Transferase

3. Evyn's health condition between 2 and 14 months of ages and vaccines given

Evyn's illnesses and medications and vaccines given between 2 and 14 months of age are described below. Briefly, Evyn received 7 vaccines at 2 months of age. He also received these vaccines at 4 and 6 months of age. Evyn was given a total of 21 vaccines between the age of 2 and 6 months [3].

Evyn suffered from bronchitis and bacterial infections at the age of 7.5 months and was treated with antibiotics and Dep medrol (Methylprednisolone). He suffered from bronchitis after 8 days of his treatment with Dep medrol and was treated again with Dep medrol. Evyn was hospitalized at the age of 8 months due to viral infections and severe thrombocytopenia [3].

Furthermore, Evyn developed bronchitis, fungal infections, and viral infections at the age of 10.5-12 months. He was given 6 vaccines at the age of 12 months while he was sick. Some of these vaccines contain attenuated live viruses. Evyn suffered from respiratory arrest on April 21, 2007. He was 14-month-old. He was sick during the six weeks prior to his respiratory arrest and had lost weight [3].

3.1 Evyn's illness reported at 2 months of age and vaccines and treatment given

Evyn appeared sick on April 26, 2006. He spitted-up after feedings and appeared fussy. His pediatrician examined him, suspected Gastroesophageal Reflux Disease (GERD), and prescribed Zantac and Reglan.

Evyn weighed 4.0 kg and gained 17.1 g/day during his first two months of life. His length and head circumference (HC) were 58.4 cm and 37.5 cm, respectively. His length gain rate

and HC growth rate were 3.33 cm/month and 1.81 cm/month, respectively.

Evyn was given 7 vaccines that include: Haemophilus influenzae type b (Hib), Pneumococcal conjugate vaccine (Prevnar), and Pediarix [Diphtheria and Tetanus Toxoids and Acellular Pertussis Adsorbed, Hepatitis B (Recombinant), and inactivated Poliovirus vaccine combined].

3.2 Evyn's illness reported at 4 months of age and vaccines and treatment given

Evyn was sick on June 23, 2006 and admitted to the Northwest Texas hospital. A blood analysis revealed that Evyn had elevated white blood cell and lymphocytes counts, which indicates bacterial infections (Table 2). He had an elevated platelet count of 668 x 10³/μL and the rest of his hematology values were within the normal range (Table 3).

Evyn's serum chemistry values were within the normal range (Table 4). He also had a normal T4 level of 9.2 μg/dL (normal range = 6.1-12.2). Evyn's urine analysis revealed normal result except for the specific gravity was below the normal range (Table 5).

Evyn's weight was 5273 g (3 percentile). His length and head circumference were 61.6 cm (25 percentile) and 40.4 cm (10 percentile), respectively. Evyn was vaccinated with Pediarix (5 vaccines), Hib, and Prevnar.

Table 2. Evyn's white blood cell and differential counts measured on June 23, 2006

Measurements	Values	Reference Range
WBC x 10 ³ /μL	21.3	6.9-15.7
Neutrophil x 10 ³ /μL	4.05	1.9-8.0
Neutrophil % of total WBC	19.0	16-52
Lymphocyte x 10 ³ /μL	15.76	0.9-5.2
Lymphocyte % of total WBC	74	32-68
Atypical lymphocyte x 10 ³ /μL	1.07	0.0-0.4
Monocyte x 10 ³ /μL	0.21	0.1-1.0
Esonophil x 10 ³ /μL	0.21	0.0-0.08

Table 3. Evyn's hematology values measured on June 23, 2006

Measurements	Values	Reference Range
RBC x 10 ⁶ /μL	4.61	3.5-4.7
HGB (g/dL)	11.7	9.7-12.2
HCT %	37.1	28.7-36.1
MCV (FL)	80.6	73.6-86.6
MCH (PG)	25.4	24.5-29.1
MCHC (g/dL)	31.5	32.0-35.1
RDW %	12.9	12.6-15.5
Platelet x 10 ³ /μL	668	275-566

3.3 Vaccines given to Evyn at 6 months of age

Evyn received his third injection of Pediarix (5 vaccines), Hib, and Prevnar on August 25, 2006. His weight was 6.425 kg (10 percentile). His length and head circumference were 66.04 cm (25-50% percentile) and 41.2cm (10 percentile), respectively. He was fed Enfaml formula milk and baby food.

Table 4. Evyn's serum values measured on June 23, 2006

Measurements	Values	Reference Range
Sodium (mM/L)	138	138-146
Potassium (mM/L)	4.6	3.6-5.0
Chloride (mM/L)	106	101-112
CO ₂ (mM/L)	21	24-31
Glucose (mg/dL)	83	70-105
BUN (mg/dL)	11	5.0-15.0
Creatinine (mg/dL)	0.3	<0.7
T. Bilirubin (mg/dL)	0.7	0.2-1.0
Total protein (g/dL)	5.7	5.6-7.2
Albumin (g/dL)	3.8	3.5-5.0
Calcium (mg/dL)	10.4	7.3-12.0
Alk. Phosphotase (U/L)	219	50-260
SGOT (U/L)	55	13-64
SGPT (U/L)	31	3-37
Anion GAP	16	6-16

Table 5. Evyn's urine analysis measured on June 23, 2006

Measurements	Values	Reference Range
Color	Straw	Yellow
Appearance	Clear	Clear
Specific gravity (g/mL)	1.003	1.005-1.030
Protein (mg/dL)	Neg.	Neg.
Glucose (mg/dL)	Neg.	Neg.
Ketones	Neg.	Neg.
Clinitest	Neg.	Neg.
Bilirubin	Neg.	Neg.
Blood	Neg.	Neg.
Nitrite	Neg.	Neg.
Leuk. Esterase	Neg.	Neg.
Urobilinogen (mg/dL)	1.0	0.2-1.0
RBC/HPF	<1	0-4
WBC/HPF	<1	0-4

3.4 Evyn's illness at the age of 7.5-8.0 months and treatment with corticosteroids

Evyn was sick on three occasions in October of 2006 and treated with antibiotics, albuterol and Dep medrol (methylprednisolone). On October 4th, Evyn was coughing and his throat culture was positive for Group A Beta-Streptococcus. He was treated with Omnicef antibiotic (100 mg PO Q D x 8 days). His weight was 6.755 kg.

Evyn was coughing again on October 12th and had fever. He was choking on his mucus and vomiting. He suffered from bronchitis and was treated with albuterol and Dep medrol (Methylprednisolone) 15 mg IM. His weight was 7.0 kg.

Furthermore, Evyn suffered from febrile illness on October 18th and was hospitalized for three days. He was coughing and had a temperature of 102.6°F. His weight was 6.600 kg and had lost 400 g in 6 days (-66.6 g/day).

A blood analysis performed on October 18th revealed that Evyn had a platelet count of 31 x 10³/μL. He was suffering from thrombocytopenia. His platelet count returned to a normal level on October 21st (Table 6). Evyn had a slightly elevated white blood cell count on October 21st (Table 7). His serum analysis revealed normal result (Table 8).

Table 6. Evyn's blood analyses performed on Oct. 18 and 21, 2006

Measurements	10/18 (1310)	10/21 (1024)	Reference Range
RBC x 10 ⁹ /μL	4.32	4.37	4.2-5.4
HGB g/dL	11.4	11.5	10.5-12.1
HCT %	33.3	33.9	31.0-40.5
MCV (fL)	77.0	77.6	80.0-94.9
MCH (PG)	26.5	26.3	28.4-32.0
MCHC (g/dL)	34.4	33.9	32.6-34.8
RDW %	14.1	14.3	11.5-14.5
Platelet x10 ³ /μL	31	250	250-407

Table 7. Evyn's white blood cell and differential counts measured in October of 2006

Measurements	Values 10/18	Values 10/21	Reference Range
WBC x 10 ³ /μL	9.0	13.7	4.5-11.0
Neutrophil % of total WBC	31.4	20	15-35
Lymphocyte% of total WBC	51.9	59	53-65
Monocyte x 10 ³ /μL	15.8	6	3-15

Table 8. Evyn's serum analysis performed in October 2006

Measurements	Values on 10/18	Reference Range
Sodium (mM/L)	137	138-146
Potassium (mM/L)	4.3	3.6-5.0
Chloride (mM/L)	104	101-112
CO ₂ (mM/L)	22	24-31
Glucose (mg/dL)	98	74-118
BUN (mg/dL)	9.0	5.0-17.0
Creatinine (mg/dL)	0.3	0.1-0.6
T. Bilirubin (mg/dL)	0.4	0.2-1.0
Total protein (g/dL)	6.0	5.6-7.2
Albumin (g/dL)	3.6	3.5-5.0
Calcium (mg/dL)	9.8	7.3-12.0
Alk. Phosphotase (U/L)	172	50-260
SGOT (U/L)	46	13-64
SGPT (U/L)	20	3-37
Anion GAP	11	6-16
Osmolality (mOsm/kg)	273	265-285
C-Reactive protein (mg/dL)	0.90	0.0-1.0

3.5 Evyn's illness at 10.5 to 11 months of age and treatment with corticosteroids

Evyn was sick on January 4, 2007. He was coughing, had a temperature of 102°F, and suffering from bronchitis. His appetite was poor and he weighed 8.0 kg. He was treated with albuterol and Dep medrol (Methylprednisolone).

Evyn vomited on January 22nd and had trouble breathing. He developed thrush as a result of his treatment with corticosteroids. He was treated with Diflucan (antifungal) for 13 days. His weight was 8.181 kg and had gained 181 g in 18 days (10 g/day).

3.6 Evyn's illness at 12 months of age and vaccines given

Evyn was coughing and had chest congestion on February 26, 2007. His temperature was 100.9°F and treated with Tylenol. His weight was 8.409 kg and had gained 228 g in 35 days (6.5 g/day).

He was given 6 vaccines on February 28, 2007. These include Hepatitis A, Prevnar, and Proquad (measles, mumps, rubella, and chickenpox vaccines). Measles, mumps, and rubella vaccines contain live attenuated viruses. Evyn's weight was 8.3 kg (3rd percentile) and had lost 109 g in the 2 days prior to vaccination as a result of his acute illness. His length and head circumference were 73.7 cm (50 percentile) and 45.8 cm (25 percentile), respectively.

3.7 Evyn's illness at the age of 12.5 and 13.5 months and treatment given

Evyn had a high temperature of 103.5°F on March 8, 2007 and was taken to the Northwest Texas Hospital. His examination revealed a pulse rate of 167/minute and a respiratory rate of 18/minute. His weight was 8.9 kg. He was treated with Motrin and Tylenol.

Furthermore, Evyn suffered from tonsillitis and bronchitis on April 9th. He was coughing and had runny nose. His temperature was 102.6°F. His weight was 8.818 kg and had lost 82 g in 32 days. He was treated with Motrin.

3.8 Evyn's illness observed during the 6 days prior to his respiratory arrest

Michael Wayne Garrard watched Evyn on April 15th, 16th, 20th, and April 21, 2007. Michael is a 32-year-old white male. He provided the following observations concerning Evyn's health:

1) Michael saw Evyn run into a couch 2 or 3 times while he was playing on April 15, 2007. He changed his diaper on April 16th and found several bruises on Evyn's head, ear, face, back, chest, belly, and legs. Michael asked Evyn's mother about these bruises and she said that maybe Evyn fell.

2) Michael was sick and throwing up on April 19th. He got off work and went to Evyn's mother's house to sleep. He saw Evyn was screaming and crying. On April 20th, Michael did not go to work because he was sick. Evyn's mother asked him to watch Evyn and his sister (3-4 years old) until she found a new daycare. She left for work at 0900 and Michael took the children to his house.

Evyn was throwing up, screaming and crying, and had diarrhea. Michael changed Evyn's diaper and saw bruises. Michael called Evyn's mother and reported Evyn's condition to her. She came home at 1200 and she did not return to work. Evyn continued to scream, cry, vomit, and had diarrhea. Michael stated that Evyn did not hold anything down during that day and night and appeared very weak.

3) Michael and Evyn's mother stayed home with the children on April 21st. Evyn was very sick. He was throwing up and had diarrhea. In the afternoon, Evyn's mother went to the store to buy food and left Evyn and his sister with Michael at home. Evyn's sister pushed Evyn into a glass table while Michael was washing the dishes. Michael saw a cut inside Evyn's lip.

Michael noticed that Evyn went limp and his eyes rolled to the back of his head while he was changing his diaper. He performed CPR and saw blood was coming from Evyn's mouth. He called Evyn's mother and she called 911 [4].

3.9 The paramedics observations and treatments given

The EMS dispatched at 1648 on April 21, 2007 and arrived at the scene at 1655. They found Evyn was not breathing. Blood and fluid was coming from his mouth. His skin was cool and dry. He had several bruises on his back, abdomen, and ear at various stages of healing.

They suctioned Evyn's airway and intubated him. Evyn was ventilated with oxygen. He had a pulse rate of 116-132/minute and a temperature of 93.6°F. His heart was monitored. The EMS transported Evyn to Northwest Texas Hospital. They left the scene at 1718 and arrived at the hospital at 1730 [5].

4. Evyn's hospitalization on April 21-23, 2007, clinical tests, diagnoses, and treatments given

The EMS brought Evyn to the ER at the Northwest Texas Hospital at 1730 on April 21, 2007. He was intubated, unconscious, and unresponsive. His blood oxygen saturation was 86%. His heart monitor showed sinus tachycardia at 135 beats/minute. He had a temperature of 95.6°F and his abdomen was distended. His weight and length were 8.9 kg and 75 cm, respectively [6].

A blood analysis performed at 20 minutes following Evyn's admission to the hospital (FAH) revealed a high white blood cell count (WBC) of $21.8 \times 10^3/\mu\text{L}$. He was treated with antibiotics (ciprofloxacin and tobramycin). However, his white blood cells and neutrophils (segmented and band) counts stayed elevated at about 18 hours FAH. His WBC returned to a normal level at 26 hours FAH due to the treatment with antibiotics (Table 9). Evyn's blood culture was positive for *Streptococcus pneumoniae* and *Haemophilus influenzae* (Table 10).

Evyn's blood analysis performed at 20 minutes FAH showed that he was suffering from anemia. His red blood cell count and hemoglobin level were below the normal range. He was given blood and red cell transfusions that raised his red blood cell count and hemoglobin level to a normal range (Tables 11, 12).

Evyn's chest and abdomen CT scan performed at 50 minutes FAH showed diffuse abnormal density in the lungs and periportal edema in the liver. His head CT scan taken at 50 minutes FAH showed global anoxia and increased attenuation along the falx. The increased attenuation may represent a subdural hematoma or caused by the decreased density in the adjacent brain parenchyma.

A blood analysis performed at about 2 hours FAH showed that Evyn had metabolic acidosis. He had a blood pH of 7.24, a PCO₂ level of 27.2 mm Hg, and a bicarbonate level of 11.5 mmol/L. He was treated with sodium bicarbonate IV that raised his blood pH to a critically high level of 7.60 (Table 13).

A blood analysis performed at 1.6 hours FAH revealed that Evyn's liver serum enzymes were elevated. His AST, ALT, and Alkaline phosphatase levels were 2-3 times the average normal level (Table 14). The majority of the blood clotting factors is synthesized in the liver and a significant liver damage causes reduction in the production of clotting factors. Evyn's prothrombin time (PT) and international normalized ratio (INR) were elevated at 2 hours FAH and they increased by 11-13% at 18 hours FAH (Table 15).

Evyn's blood glucose level became elevated at 8 hours FAH and was treated with insulin. However, his blood glucose reached a high level of 541 mg/dL at 43 hours FAH in spite of the treatment with high doses of insulin (Table 16). A blood analysis performed at 20 hours FAH revealed that Evyn had an elevated serum amylase level of 392 IU (normal range: 98-192). His urine analysis performed at about 22 hours FAH showed a moderate amount of ketone bodies and a trace amount of glucose (Table 17).

Evyn's blood sample taken at 18 hours FAH for bacterial culture showed heavy growth of *S. pneumonia* and *H. influenzae*. Gram stain study of Evyn's sputum revealed the presence of a significant growth of Gram-positive cocci and a significant amount of white blood cells. Repeated blood culture performed on Evyn's blood sample taken at 26 hours FAH revealed moderate growth of *S. pneumonia* (Table 10). These clinical tests indicate that Evyn suffered from bacterial infections, septicemia, and pneumonia.

Evyn's urine and serum analyses indicate that he also suffered from kidney bacterial infections and kidney damage (Tables 17, 18, 19). A urine analysis performed at 20 hours FAH revealed the presence of albumin, red blood cell, white blood cells, and bacteria in Evyn's urine. A serum analysis revealed that Evyn's albumin and protein levels were lower than the normal range.

Evyn's serum creatinine level at 6 hours FAH was twice the average normal level. In addition, Evyn developed hypernatremia, hyperchloremia, hyperkalemia, hyperphosphatemia, and hypermagnesemia following his admission to the hospital. His blood osmolality was also increased significantly (Table 19).

A blood analysis performed at 20 hours FAH showed Evyn had elevated levels of creatine kinase (CK), CK-MB, lactic dehydrogenase (LDH), Myoglobin-P/S, and troponin-I (Table 20). His electrocardiogram performed at 21.5 hours FAH showed sinus tachycardia and mild biventricular hypertrophy. Furthermore, Evyn's echocardiogram studies performed at 22 FAH revealed that he had moderate to severe left ventricle dysfunction. His left atrium was also dilated and had left ventricle mitral valve insufficiency.

Evyn was treated with several medications but he did not show an improvement. He was given Acetaminophen, albuterol; antibiotics (ciprofloxacin and tobramycin); Amphotericin B (antifungal); Ativan; Dopamine; Fentanyl; Fresh Frozen Plasma (FFP), IV Fluids; Hextend; insulin; Lasix, KCL; magnesium sulfate; Papaverine; Proventil; Ranitidine, Solumdro; T 4; Tromethamine; and vitamin K.

Evyn was pronounced brain dead at 1210 on April 22nd. He was maintained on life support with mechanical ventilation and endotracheal intubation until 1315 on April 23 and his organs were harvested for donations. The clinical data collected during Evyn's hospitalization are described below (Section 4.1-10).

4.1 Evidence of bacterial infections and septicemia

A blood sample analyzed at 20 minutes FAH revealed that Evyn had a high white blood cell count (WBC) of $21.8 \times 10^3/\mu\text{L}$. He was treated with antibiotics (ciprofloxacin and tobramycin). His white blood cells and neutrophil (segmented and band) counts stayed elevated at about 18 hours FAH. His WBC returned to a normal level at 26 hours FAH due to the treatment with antibiotics (Table 9).

Evyn's blood sample taken at about 19 hours FAH for bacterial culture showed a heavy growth of *Streptococcus pneumonia* and *Haemophilus influenzae*. Gram stain study of his sputum revealed the presence of a significant growth of Gram-positive cocci and a significant amount of white blood cells.

Repeated blood culture performed on Evyn's blood sample taken at 26 hours FAH revealed a moderate growth of *S. pneumonia* (Table 10). These clinical tests indicate that Evyn suffered from bacterial infections.

In addition, Evyn's blood sample taken at 2 hours FAH showed that he was suffering from lymphocytopenia. He had a total blood lymphocyte count of $990/\mu\text{L}$. His lymphocyte count reached a very low level of $392/\mu\text{L}$ at 26 hours FAH (Table 9). Lymphocytopenia in children is defined as a blood lymphocyte count of less than $3000/\mu\text{L}$ [7, 8].

Table 9. Evyn's white blood cells and differential counts measured on April 21-23, 2007

Date	Time	WBC $\times 10^3/\mu\text{L}$	Seg. Neutrophils %	Seg. Band		Lymphocytes %	Lymphocytes $\times 10^3/\mu\text{L}$	Monocyte %
				Neutrophils $\times 10^3/\mu\text{L}$	Neutrophils %			
4/21/07	1750	21.8	47	10.25	3	41	8.94	8
	1928	24.8	80	19.84	2	4	0.99	14
4/22/07	0230	21.4	68	14.55	10	13	2.78	9
	1330	16.2	78	12.64	7	7	1.13	8
	1955	9.8	77	7.55	8	4	0.392	10
4/23/07	0113	10.1	74	7.47	16	6	0.606	4
	0513	8.7	44	3.83	33	17	1.48	8
	1010	9.2	49	4.51	24	23	2.12	4
Reference Range		4.5-11	15-35	1.5-8.5	3	61	4-10.5	3-15

Table 10. Results of blood cultures and sputum Gram stain performed at 19 to 26 hours following Evyn's admission to the hospital

Date and Time of collection	Sample	Findings
4/22/07 at 1414	Blood Culture	• Heavy growth of <i>Streptococcus pneumoniae</i> • Heavy growth of Gram-negative rods, <i>Haemophilus</i> species
4/22/07 at 1414	Sputum gram stain	• Many Gram-positive cocci in pairs • Few Gram-negative rods • 11-25 WBC's/OIF
4/22/07 at 2123	Blood culture	• Moderate growth of <i>Streptococcus pneumoniae</i>

4.2 Evidence of anemia

A blood analysis performed at 20 minutes FAH showed that Evyn was suffering from anemia. His red blood cell count and hemoglobin level were below the normal range. He was giving blood and red cell transfusions that raised his red blood cell count and hemoglobin level to a normal range.

His platelet count was within the normal range at admission but it reduced by 40% at 26 hours FAH (Tables 11, 12). It indicates that he was suffering from disseminated intravascular coagulation (DIC).

Table 11. Evyn's hematology values measured prior and after receiving blood and red blood cell transfusions

Date	Time	RBC X 10 ⁶ /μL	Hgb g/dL	HCT %	Platelets x 10 ³ /μL
4/21/07	1750 ¹	3.98	10.2	30.7	464
	1928	4.14	10.7	32.0	490
4/22/07	0230	4.98	12.9	38.2	574
	1330	3.68	9.5	28.4	420
	1955	3.56	9.9	29.1	265
4/23/07	0113	4.78	13.5	40.0	269
	0513	4.46	12.7	37.6	249
	1010	5.04	14.5	43.4	242
Reference Range		4.2-5.4	10.5-12.1	31.0-40.5	250-470

¹ Prior to receiving blood transfusion.

Table 12. Indicators of RBC size and hemoglobin concentrations measured in Evyn's case

Date	Time	MCV fl	MCH pg	MCHC g/dL	RDW %	MPV fl
4/21/07	1750	77.2	25.7	33.3	14.8	5.5
	1928	77.1	25.9	33.5	14.5	5.5
4/22/07	0230	76.6	25.9	33.7	14.7	6.1
	1330	77.0	25.8	33.5	15.0	5.6
	1955	81.8	27.7	33.9	17.0	5.6
4/23/07	0113	83.5	28.3	33.8	17.1	5.9
	0513	84.3	28.4	33.7	17.2	5.9
	1010	86.2	28.7	33.3	16.9	5.9
Reference Range		80.0-94.9	28.4-32.0	32.6-34.8	11.5-14.5	7.2-11.1

4.3 Metabolic acidosis and alkalosis

A blood analysis performed at about 2 hours FAH showed that Evyn was suffering from metabolic acidosis. He had a blood pH of 7.24, a PCO₂ level of 27.2 mm Hg, and a bicarbonate level of 11.5 mmol/L. He was treated with sodium bicarbonate IV that raised his blood pH to a critically high level of 7.60 (Table 13).

The treatment with high doses of sodium bicarbonate has caused anoxia and brain edema in children. Fauci *et al.* reported that alkalinization of the blood with sodium bicarbonate increases the avidity of hemoglobin to bind oxygen, thus impairing the release of oxygen in peripheral tissues [7].

Table 13. Evyn's blood gases measured on April 21-23, 2007

Date	Time	pH	PCO ₂ mm Hg	HCO ₃ ⁻ mmol/L	Base Excess mmol/L
4/21/07	1907	7.244	27.2	11.5	-14.3
4/21	2025	7.285	26.0	12.1	-13.9
4/21	2120	7.407	21.5	13.2	-9.9
4/22/07	0330	7.278	26.0	11.9	-13.1
4/22	0506	7.361	21.6	12.0	-11.2
4/22	0916	7.459	29.8	20.7	-2.2
4/22	1349	7.572	26.1	25.3	3.8
4/22	1444	7.604	28.7	27.8	6.0
4/22	1814	7.528	28.9	23.5	1.6
4/22	1933	7.477	35.4	25.6	2.2
4/23/07	0029	7.517	30.1	23.9	2.0
4/23	0200	7.489	30.8	22.9	0.4
4/23	0710	7.574	21.7	19.6	-0.8
4/23	0816	7.484	32.4	23.8	1.0
4/23	0932	7.395	33.7	20.2	-3.8
Reference Range		7.3-7.4	35-50	20-24	-3+3

4.4 Liver and blood coagulation problems

A blood analysis performed at 1.6 hours FAH revealed that Evyn had elevated level of liver enzymes in serum. His serum AST, ALT, and Alkaline phosphatase levels were 2-3 times the average normal level. Evyn was treated with antibiotics and his ALT and alkaline phosphatase levels returned to a normal range at 26 hours FAH (Table 14). These data indicate that Evyn suffered from liver damage caused by bacterial infections.

The majority of the blood clotting factors is synthesized in the liver and a significant liver damage causes reduction in production of clotting factors. Evyn's prothrombin time (PT) and international normalized ratio (INR) were elevated at 2 hours FAH. They also increased by 11-13% at 18 hours FAH (Table 15). PT measures clotting factors II, V, VII, X and fibrinogen and these factors are synthesized in the liver. These data indicate that the synthesis of clotting factors in Evyn's liver was reduced.

Table 14. Evyn’s serum liver enzymes and bilirubin levels

Date	Time	AST/ SGOT (U/L)	ALT/ SGPT (U/L)	Alkaline Phosphatase (U/L)	Bilirubin Total (mg/dL)
4/21/07	1910	98	96	204	1.4
4/22/07	0230	109	115	215	2.09
4/22	1330	86	77	156	0.6
4/22	1955	76	50	110	0.3
4/23/07	0113	87	50	132	0.5
4/23	0513	78	50	134	0.5
Reference Range		15-41	11-36	38-126	0.4-2.0

Table 15. Indicators of blood coagulation measured in Evyn’s case

Measurements	4/21/07 (1928) ¹	4/22 (1330)	4/22 (1955)	4/23 (0513)	Reference Range
Prothrombin time	15	17.0	15.8	13.9	9.7-13.3
INR	1.31	1.46	137	1.23	0.8-1.2
PTT activated	20.4	31	36.7	32.7	27.5-36.3
Fibrinogen	---	---	336	---	210-482
Fibrinogen split product	---	---	>5<20	---	Less than 5 µg/mL

¹Time of the blood collection.

² Not measured

4.5 Hyperglycemia, ketone urea, and elevated serum amylase level

Evyn’s blood glucose level became elevated at 8 hours FAH and was treated with insulin. His blood glucose reached a high level of 541 mg/dL at 43 hours FAH in spite of the treatment with high doses of insulin (Table 16). A blood analysis performed at 20 FAH showed that Evyn had elevated serum amylase level of 392 IU (normal range: 98-192).

Furthermore, his urine analysis performed at about 22 hours FAH showed a moderate amount of ketone and a trace amount of glucose (Table 17). These data indicate that Evyn’s hyperglycemia was resulted from pancreatic problem.

4.6 Urine and serum analyses and indicators of kidney problems

Urine and serum analyses indicate that Evyn suffered from kidney damage as a result of bacterial infections (Tables 17, 18, 19). His urine analysis performed at 20 hours FAH revealed the presence of albumin, red blood cell, white blood cells, and bacteria. A serum analysis revealed that Evyn’s albumin and protein levels were lower than the normal range.

Evyn’s serum creatinine level at 6 hours FAH was twice the average normal level. He also developed hypernatremia, hyperchloremia, hyperkalemia, hyperphosphatemia, and hypermagnesiumia following his admission to the hospital. His blood osmolality was increased significantly (Table 19). These data indicate that Evyn’s suffered from infections and kidney damage.

Table 16. Evyn’s blood glucose levels

Date	Time	mg/dL
4/21/07	1750	99
	1910	119
	1916	157
4/22/07	0230	118
	0333	184
	0504	221
	0520	260
	0701	320
	0809	371
	0900	183
	0913	319
	1008	299
	1100	283
	1109	310
	1200	404
	1215	239
4/23/07	1339	183
	1620	295
	1901	147
	2110	162
	2400	162
	0100	156
	0411	179
	0710	134
	1000	191
	1100	283
1200	404	
1230	541	

Table 17. Evyn’s urine analyses results

Measurements	4/22/07 1504	4/23/07 0533	Reference Range
Color	Light yellow	Light yellow	Yellow
Appearance	Cloudy	Clear	Clear
Spec gravity	>1.030	1.011	1.003-1.029
pH	8.5	7.5	4.5-7.8
Albumin	2+	Trace	Negative
Glucose	1+	Negative	Negative
Reducing sugars	1+	Negative	Negative
Ketone	2+	Negative	Negative
Blood	Trace	Negative	Negative
Bilirubin (Units)	0.2	0.2	0.2
Leukocyte Est	Negative	Negative	Negative
Nitrite	Negative	Negative	Negative
WBC/HPF	6-10	0-5	0-5
RBC/HPF	6-10	0-5	0-5
Bacteria	1+	None Seen	None Seen

Table 18. Evyn’s Anion Gap (AG), creatinine, BUN, albumin (Alb.), and protein levels in serum

Date	Time	AG (mmol/L)	Creat. (mg/dL)	BUN (mg/dL)	Alb. (g/dL)	Tot. Prot. (g/dL)
4/21/07	1910	15	0.5	16	2.9	5.4
4/22/07	0230	25	1.1	13	3.8	6.8
4/22	1330	9	0.4	6	2.9	5.2
4/22	1995	10	0.4	1.0	2.3	4.4
4/23/07	0113	9	0.2	1.0	2.6	5.0
4/23	0513	8	0.3	1.0	2.7	5.2
4/23	1010	5	0.3	2.0	---	---
Reference Range		9-18	0.1-0.6	5-17	3.4-4.2	6.3-8.2

¹ Not measured

4.7 Indicators of heart problems

A blood analysis performed at 20 hours FAH showed that Evyn had elevated levels of creatine kinase (CK), CK-MB, lactic dehydrogenase (LDH), Myoglobin-P/S, and troponin-I (Table 20). They indicate that Evyn's cardiac muscles were damaged.

Table 19. Evyn's serum levels of elements and blood osmolality measure in April 21-23, 2007

Date	Time	Sodium (mmol/L)	Chloride (mmol/L)	Potassium (mmol/L)	Phosphorus (mmol/L)	Calcium (mg/dL)	Magnesium (mg/dL)	Osmola. mOsm/kg
4/21	1750	134	107	4.2	---1	---	---	---
4/21	1910	136	107	5.3	---	8.8	---	274
4/22	0230	160	123	4.5	6.3	9.3	3.3	314
4/22	1330	148	113	2.4	2.2	8.3	2.3	296
4/22	1995	141	105	3.2	6.1	7.1	1.7	277
4/23	0113	146	113	3.8	---	8.2	---	290
4/23	0513	151	117	2.9	3.4	8.6	2.6	296
4/23	1010	156	134	7.9	---	8.6	---	310
Reference Range		135-148	95-105	3.4-5.1	2.4-4.7	8.4-10.3	1.8-2.5	265-285

¹Not Measured.

Table 20. Indicators of cardiac muscle damage

Measurements	4/22/07	4/22	Reference Range
CK (CPK)	540	407	41-277 (U/L)
CK-MB	46.2	33.4	0-3 (ng/mL)
Myoglobin-P/S		31.3	
Troponin-I	0.34	0.21	0.0-0.03 (ng/mL)
LDH	392	---1	98-192 (U/L)

¹Not measured.

4.8 Minor bruises observed on Evyn's body at the hospital

Evyn had eight bruises at various stage of healing at the time of his admission to the hospital. These include: One bruise to left ear; five round shaped bruises on the right flank; and two bruises on the left and right femoral areas. No trauma was noted on Evyn's head, face, neck, back, and genitalia.

4.9 Toxicology screening test

Evyn's blood collected on April 23, 2007 tested negative for following drugs and other chemical agents: Alcohols, amphetamines, analgesics, anesthetics, anticonvulsants, antidepressants, antihistamines, antipsychotics, barbiturates, benzodiazepines, cannabinoids, cocaine/metabolites, cardiovascular agents, fentanyl, methadone, narcotics, opiates, phencyclidine, propoxyphene, salicylates, sedatives/hypnotics, stimulants, tricyclic antidepressants, and warfarin.

4.10 Metabolic screening test

Evyn's blood collected on April 24, 2007 tested for the following metabolic and congenital diseases and revealed negative results: Acylcarnitine profile; CAH 17-OHP; congenital hypothyroidism-TSH; and galactose-(Gal and Gal-1-P).

An electrocardiogram study performed at 21.5 hours FAH showed Evyn had sinus tachycardia and mild biventricular hypertrophy. Furthermore, his echocardiogram performed at 22 FAH revealed that Evyn had moderate to severe left ventricle dysfunction with associated dilated left atrium and left ventricle mitral valve insufficiency.

5. Heparin dose given to Evyn and harvesting his organs prior to autopsy

Evyn was pronounced brain dead at 1210 on April 22nd. However, he was maintained on life support system with mechanical ventilation until April 23rd to harvest his organs for donation. The harvested organs were taken one day prior to autopsy and were not examined by the medical examiner [9, 10].

The surgical team from LifeGift gave Evyn general anesthesia at 1302. Evyn's abdominal and chest cavities were opened. Evyn was given 3600 units of heparin IV to prevent the coagulation of the blood in organs and tissues and to help in the exsanguination process [9].

Heparin was allowed to circulate in the donor body and then the donor was exsanguinated. Evyn's heart; lungs; liver and vessels; kidneys; pancreas/islet cells and vessels; and small intestine were harvested for donation. These organs and tissues were not examined by the medical examiner at the time of autopsy. The clinical data described in the previous section of this report (Section 4) indicate that Evyn suffered from septicemia and lung, heart, liver, kidney, and pancreatic problems.

Heparin prevents coagulation of the blood by preventing the conversion of prothrombin to thrombin and fibrinogen to fibrin. The dose of heparin given to Evyn (3600 units) is very large compared to the therapeutic dose given to children and the medical examiner should consider heparin in his differential diagnosis when finding a fresh bleeding.

The therapeutic dose of heparin in children is 50 units/kg IV intermittent bolus, then 50 to 100 units/kg IV q 4 hours [11, 12]. Evyn's weight was 8.7 kg and he received 3600 unites of heparin. His dose was 414 units of heparin/kg, which is 8.3 times the therapeutic dose. It is expected that heparin causes bleeding in some ill children, even when it is given at the therapeutic dose [11, 12].

6. Bacterial infections, multi-organ damage, and the likely causes of Ewyn's respiratory arrest

The clinical data collected in this case clearly show that Ewyn suffered from bacterial infections (*Streptococcus pneumoniae* and *Haemophilus influenzae*) and septicemia, which caused pneumonia and damaged other organs (liver, heart, kidney, and pancreas). Pneumonia and septicemia caused anoxia, metabolic acidosis, hypotension, shock, and respiratory arrest in Ewyn's case. Below is the description of the clinical and medical studies that explain the medical events led to Ewyn's death.

6.1 Septicemia and pulmonary infections

Ewyn was admitted to the hospital at 1730 on April 21, 2007. A blood analysis performed at 20 minutes following Ewyn's admission to the hospital (FAH) revealed a high white blood cell count (WBC) of $21.8 \times 10^3/\mu\text{L}$ (Table 9). His white blood cells and neutrophils (segmented and band) count stayed elevated at about 18 hours FAH in spite of the treatment with antibiotics (ciprofloxacin and tobramycin).

A CT scan of Ewyn's chest performed at 50 minutes FAH showed diffuse abnormal density in the lungs. A Gram stain study of Ewyn's sputum revealed the presence of a significant growth of Gram-positive cocci and a significant amount of white blood cells.

Bronchoscopic studies conducted at about 26 FAH revealed evidence of pulmonary edema in Ewyn's lungs.

Ewyn's blood sample taken at about 19 hours FAH for bacterial culture showed a heavy growth of *S. pneumoniae* and *H. influenzae*. Repeated blood culture performed on Ewyn's blood sample taken at 26 hours FAH revealed a moderate growth of *S. pneumoniae* in spite of treatment with antibiotics (Table 10).

Ewyn's lungs were harvested prior to autopsy and were not examined by the medical examiner. *S. pneumoniae* and *H. influenzae* are the leading causes of pneumonia in children as shown by the clinical studies described below. Pneumonia and septicemia should be considered in this case as the primary causes of Ewyn's respiratory arrest and death.

1) Nascimento-Carvalho evaluated data from 9 studies conducted in North America and Europe dealing with the etiology of pneumonia in children. The etiology of pneumonia was established in 62% of studied (range 43%-88%) by the use of noninvasive specific methods for microbiologic diagnosis. The most often identified agents were *S. pneumoniae* (22%), respiratory syncytial virus (RSV) (20%), *H. influenzae* (7%), and *Mycoplasma pneumoniae* (15%) [13].

Furthermore, they evaluated data from 8 studies conducted in South America on the etiology of pneumonia in children. Bacteria were recovered from 56% (range 32%-68%) of severely ill children studied by lung aspirate. The most often isolated bacteria were *S. pneumoniae* (33%) and *H. influenzae* (21%) [13].

2) McCracken stated that *S. pneumoniae* is recognized as an important cause of pediatric pneumonia regardless of age in

both the inpatient and outpatient setting. In developed countries, *S. pneumoniae* probably accounts for 25 to 30% of cases of pediatric community-acquired pneumonia [14].

3) Rudan *et al.* stated that childhood pneumonia is the leading single cause of mortality in children aged less than 5 years. The incidence in this age group is estimated to be 0.29 episodes per child-year in developing and 0.05 episodes per child-year in developed countries. This translates into about 156 million new episodes of childhood pneumonia each year worldwide [15].

Of all community cases, 7-13% are severe enough to be life threatening and require hospitalization. Pneumonia is responsible for about 19% of all deaths in children aged less than 5 years. Recent studies have identified *S. pneumoniae*, *H. influenzae* and respiratory syncytial virus as the main pathogens associated with childhood pneumonia [15].

4) Burgner and Richmond reported that the burden of pneumonia in Australian children is significant with an incidence of 5-8 per 1000 person-years. Pneumonia is a major cause of hospital admission in children less than 5 years of age. *S. pneumoniae* is the most common bacterial cause in children under 5 years of age [16].

5) Sung *et al.* studied the epidemiologic and etiologic features of cases of pneumonia among 1,740 children admitted to a teaching hospital in Hong Kong over a 3-year period. Of the patients, 23% were < 1 year old and 69% were < 5 years old. The incidence of pneumonia requiring admission to the hospital was 6.4 episodes per 1,000 children per year for those < 5 years of age. The overall case fatality rate was 0.15% among patients who did not have severe underlying disease before contracting pneumonia [17].

A bacterial etiology was confirmed by blood culture for only 2% of patients. However, culture of sputum or nasopharyngeal aspirates yielded predominant or pure growth of one bacterial agent in 17% of cases. *H. influenzae* was the bacterial agent most frequently isolated from nasopharyngeal aspirates or sputum, followed by *S. pneumoniae* and *Staphylococcus aureus* [17].

6) Hsieh *et al.* reported that *S. pneumoniae* is an important pathogen causing sepsis, sinusitis, otitis media, bacterial meningitis, and bacterial pneumonia. It results in global morbidity and mortality each year. The burden of pneumococcal disease is highest in children and the elderly. Treatment of pneumococcal infection has been hampered by the complexity of the host immune response. In recent decades, the increase of *S. pneumoniae* strains' resistance to beta-lactam antibiotics and other classes of antimicrobials has made treatment even more complicated [18].

7) Hortal *et al.* evaluated 541 cases of pneumonia in children admitted to the Children's Hospital in Uruguay. Etiology was determined in 47.7% of the 541 pneumonia cases, involving 283 pathogens of which 38.6% were viruses and 12.6% bacteria. Bacteria predominated in ages between 6 and 23 months. The most important bacterial agents were *S. pneumoniae* (64%) and *H. influenzae* (19%) [19].

8) Espinola Docio *et al.* evaluated sixty-three patients with parapneumonic pleural effusion. The most common aetiology was *S. pneumoniae*. In 65 % of patients pleural effusion was an empyema and in 33 %, it was an exudate. In all patients with C-reactive protein below 100 mg/L, the effusion was an exudate, whereas 81 % of patients with C-reactive protein above 170 mg/L had an empyema, $p < 0.05$ [20].

9) Yao and Yang studied diseases caused by *S. pneumoniae* in Chinese children. They stated that *S. pneumoniae* is an important pathogen of pyogenic meningitis, pneumonia, and other infectious diseases in children. The distribution of serotypes of *S. pneumoniae* showed great diversity in several studies in various cities in China during different years [21].

10) McCluskey *et al.* stated that *S. pneumoniae* is an important human pathogen associated with pneumonia, septicaemia, meningitis, and otitis media. It is estimated to result in over 3 million child deaths worldwide every year [22].

11) Leelarasamee *et al.* evaluated the medical records of 205 cases of hospitalized patients with specimens cultured positive for *S. pneumoniae*. Nineteen (9.3%) patients were less than 2 years old, 29 (14.1%) were between 2 and 13 years, 99 (48.3%) were between 14 and 60 years, and 58 (28.3%) were over 60 years of age. Pneumonia (50.7%) and acute exacerbation of chronic obstructive pulmonary disease or infected bronchiectasis or bronchopneumonia (21.0%) were the most frequent diagnoses, followed by meningitis (14.6%) and primary sepsis without localized lesion (8.3%). The mortality rate during the first 7 days of hospitalization was 28.8%, and thereafter, 11.7%. [23].

12) Farha and Thomson stated that the available data in the developing world suggest a burden of pneumonia in the order of 10-15 cases/1000 children per year and a hospital admission rate of 1-4/1000 per year. Both incidence and hospital admission are greatest in the youngest children and rapidly fall after the age of 5 years. *S. pneumoniae* is the most common bacterial cause [24].

13) Greenwood stated that pneumonia causes about three million deaths a year in young children. *S. pneumoniae* is the most important bacterial cause of pneumonia in young children and so is likely to be responsible for a high proportion of these deaths. *S. pneumoniae* is also responsible for a substantial proportion of the 100,000-500,000 deaths that occur from meningitis in children each year [25].

14) Funkhouser *et al.* reported that *H. influenzae* is one of the leading causes of severe bacterial infection in children of developing regions. It causes 30% of the cases of culture-positive pneumonia and 20%-60% of the cases of bacterial meningitis. In infants and children, the majority of isolates from cerebrospinal fluid and blood and 16%-38% of pulmonary isolates are *H. influenzae* type b. [26].

6.2 Evyn's cardiac problems

Evyn's blood culture was positive for *S. pneumoniae* and *H. influenzae* growth. He suffered from acute heart problems. A blood analysis performed at 20 hours FAH showed that Evyn had elevated levels of creatine kinase (CK), CK-MB, lactic dehydrogenase (LDH), Myoglobin-P/S, and troponin-I (Table 20).

The levels of these biomarkers in serum are used to evaluate the severity of damage in cardiac muscle and cardiac dysfunction. For example, Panteghini *et al.* investigated the ability of a single-point cTnI, measured with a second-generation assay (Access AccuTnI), to estimate infarct size and assess LV function in patients with a first myocardial infarction (AMI). Serum levels of contractile protein troponin I (cTnI) were measured at 12 and 48 h after admission in 63 consecutive AMI patients.

LV function was evaluated by gated single-photon emission computed tomography (SPECT) and infarct size was estimated by CK-MB peak and SPECT myocardial perfusion. LV function and infarct size were evaluated by SPECT before hospital discharge. SPECT was also repeated 3 months later [27].

Significant correlations ($p < 0.001$) were found between cTnI at 12 and 48 h and both the peak CK-MB ($r = 0.61$ and $r = 0.82$, respectively) and the perfusion defect size at SPECT ($r = 0.55$ and $r = 0.61$, respectively). cTnI at 12 and 48 h were inversely related ($p < 0.001$) to LV ejection fraction (LVEF) assessed both early ($r = -0.45$ and $r = -0.57$, respectively) and 3 months after AMI ($r = -0.51$ and $r = -0.69$, respectively). cTnI > 14.8 microg/L at 48 h predicted an LVEF $< 40\%$ at 3 months with a sensitivity of 100% [95% confidence interval (CI) 73.5-100%], specificity of 65% (CI 49-79%), and a negative predictive value of 100% [27].

Takala and Ruokonen stated that septic shock causes an acute impairment of tissue perfusion, characterized by hypotension, low systemic vascular resistance and increased blood levels of lactate. Myocardial dysfunction is common despite hyperdynamic circulation, and may limit the patient's ability to respond to increase tissue oxygen demand [28].

Oliveira *et al.* evaluated serum level of contractile protein troponin I (cTnI) in 218 children admitted to the hospital within the 24 hrs of sepsis and septic shock. Abnormal serum levels of cTnI occurred in ten (4.5%) patients, significantly more frequent in the septic shock group than in sepsis group (13% vs. 0.7%, respectively). Frequency of elevated serum cTnI was significantly higher in non-survivors than in survivors (5 of 27 vs. 5 of 191, respectively; $p = 0.003$) [29].

Furthermore, Tzivoni *et al.* conducted study to correlate peak level and area under the curve (AUC) of troponin T to that of CK and CK-MB and with single-photon emission computed tomographic infarct size and left ventricular function in patients with ST elevation myocardial infarction. They included 267 patients who underwent primary coronary intervention within 6 hours of onset of symptoms. All had repeated measurements of troponin T, CK, and CK-MB. Infarct size and left ventricular function were assessed by single-photon emission computed tomography performed on days 7 and 30.

Mean infarct sizes were 14% on day 7 and 10% on day 30, and mean ejection fractions were 42% on day 7 and 45% on day 30 after the acute infarct. Very high correlation ($r > 0.85$, Spearman correlation) was found between peak level and AUC of troponin T, CK, and CK-MB. Similar high correlation was found between peak level and AUC of troponin, CK, and CK-MB with single-photon emission computed tomographic infarct size ($r > 0.70$) [30].

An electrocardiogram study performed at 21.5 hours FAH showed Evyn had sinus tachycardia and mild biventricular hypertrophy. Furthermore, his echocardiogram performed at 22 FAH revealed that Evyn had moderate to severe left ventricle dysfunction with associated dilated left atrium and left ventricle mitral valve insufficiency.

Bacteria have also caused pericarditis and endocarditis in children and adults as shown by the clinical studies described below. Evyn had mitral valve insufficiency and it is likely that he had endocarditis. Evyn's heart was harvested for donation prior to autopsy and it was not examined by the medical examiner to rule out infections.

1) McMahon *et al.* evaluated 20 patients with features of endocarditis who had positive ultrasonic findings. They had a median age of 6.5 years and a range from 0.14 to 8.5 years. Organisms isolated included *S. mitis* in 4 patients, *S. pneumoniae* in 2 patients, *S. sanguis* in 1, *Staphylococcus aureus* in 3, *Staphylococcus epidermidis* in 1, and *Enterococcus* in 2. Cultures proved negative in 7 patients. Both patients infected with *S. pneumoniae* had rupture of a sinus of Valsalva [31].

2) Ishiwada *et al.* analyzed the clinical course, treatment, and outcome of 9 patients (aged 7 months to 4 years) with infective endocarditis (IE) due to *S. pneumoniae*. Pneumococcal IE was associated with congenital heart disease in 7 patients and accompanied by other systemic infections including meningitis, pneumonia and otitis media, in 4 patients. Seven patients were treated with carbapenem. Three underwent cardiac surgery due to cardiac failure and/or vegetation. One died due to septic shock on the first day of hospitalization [32].

3) Cabezuelo Huerta *et al.* evaluated 4 children with acute purulent pericarditis whose ages ranged between 7 months and 7 years. Pathogens identified were *H. influenzae*, *Staphylococcus aureus*, *S. pneumoniae* and *Neisseria meningitidis* [33].

4) Murillo Vallés *et al.* reported a case of a previously healthy, 17-month-old boy who developed endocarditis due to *S. pneumoniae*. He was treated with beta-lactam antibiotics during the course of pneumonia. He developed cardiorespiratory deterioration and a heart murmur. Mitral valve vegetation was identified by transthoracic echocardiography. Prosthetic mitral replacement was performed and *S. pneumoniae* was identified by polymerase chain reaction (PCR) in the pathological specimen [34].

6.3 Liver damage

Evyn suffered from a bacterial infection and sepsis that caused liver injury. A CT scan of Evyn's abdomen performed at

50 minutes FAH showed portal edema of the liver. Evyn's liver was harvested for donation prior to autopsy and was not examined by the medical examiner.

A blood analysis performed at 1.6 hours FAH revealed that Evyn had elevated liver enzymes levels in serum. His serum AST, ALT, and Alkaline phosphatase levels were 2-3 times the average normal level. Evyn was treated with antibiotics and his ALT and alkaline phosphatase levels returned to a normal level at 26 hours FAH (Table 14).

Spapen stated that sepsis causes significant alterations in the hepatic macro- and microcirculation. Microvascular blood flow disturbances are thought to play a pivotal role in the development of sepsis-induced multiorgan failure [35].

Redistribution of intrahepatic blood flow in concert with a complex interplay between sinusoidal endothelial cells, liver macrophages, and passing leukocytes lead to a decreased perfusion and blood flow velocity in the liver sinusoids. Activation and dysfunction of the endothelial cell barrier with subsequent invasion of neutrophils and formation of microthrombi further enhance liver tissue ischemia and damage [35].

Koskinas *et al.* evaluated the histology of biopsy of individuals that died due to sepsis. Needle liver biopsies obtained immediately after death from 15 consecutive patients with sepsis and no underlying liver disease. Histology of liver biopsy specimens showed portal inflammation in 73.3%, centrilobular necrosis in 80%, lobular inflammation in 66.7%, hepatocellular apoptosis in 66.6% and cholangitis/cholangiolitis in 20% of patients.

Mixed hepatitic/cholestatic type of liver injury was observed in 6/15 (40%) patients and hepatic in 9/15 (60%). Steatosis was observed in 11/15 (73.3%) patients affecting 5%-80% of liver parenchyma. Among the histological features, the presence of portal inflammation in liver biopsy was associated with increased hospitalization in the ICU prior death ($P=0.026$) [36].

6.4 Pancreatic injury

Sepsis also caused pancreatic injury in Evyn's case. Evyn's blood glucose level was elevated at 8 hours FAH and was treated with insulin. His blood glucose reached a high level of 541 mg/dL at 43 hours FAH in spite of the treatment with high doses of insulin (Table 16). His urine analysis performed at about 22 hours FAH showed a moderate amount of ketone bodies (Table 17). Furthermore, a blood analysis performed at 20 FAH showed that Evyn had elevated serum amylase level of 392 IU (normal range: 98-192).

The susceptibility of the pancreas to ischemia/reperfusion injury has been demonstrated in experimental studies and in clinical settings such as cardiopulmonary bypass, hemorrhagic shock, and transplantation of the pancreas. Oxygen free radicals, activation of polymorphonuclear leukocytes, failure of microvascular perfusion, cellular acidosis, and disturbance of intracellular homeostasis appear to be important factors/mechanisms in the pathogenesis of ischemia/reperfusion-induced acute pancreatitis [37].

Evyn suffered from metabolic acidosis and disseminated intravascular coagulation (DIC). At about 2 hours FAH, Evyn had a blood pH of 7.24, a PCO_2 level of 27.2 mm Hg, and a

bicarbonate level of 11.5 mmol/L. His platelet count was within the normal range at admission but it reduced by 40% at 26 hours FAH (Tables 11, 12). It indicates that Evyn was suffering from DIC. Blood clot logged in small blood vessels can cause ischemia and pancreatic injury.

Zhou and Chen stated that ischemia possibly acts as an initiating factor of pancreatic microcirculatory injury in acute pancreatitis, or as an aggravating/continuing mechanism. The end-artery feature of the intralobular arterioles suggests that the pancreatic microcirculation is highly susceptible to ischemia. Various vasoactive mediators, as bradykinin, platelet activating factor, endothelin and nitric oxide participate in the development of microcirculatory failure [38].

6.5 Kidney damage

Urine and serum analyses indicate that Evyn suffered from kidney bacterial infections and kidney damage (Tables 17, 18, 19). His urine analysis performed at 20 hours FAH revealed the presence of albumin, red blood cell, white blood cells, and bacteria. A serum analysis revealed that Evyn's albumin and protein levels were lower than the normal range.

Large quantities of plasma proteins normally flow through the glomerular capillaries but do not enter the urinary space. Both charge and size selectivity prevents virtually all of albumin, globulin, and other large-molecular-weight protein from crossing the glomerular wall. The glomerular basement membranes trap most of large protein except in cases of damage to the membranes, which allow the passage of protein into the urine [7].

Evyn's serum creatinine level at 6 hours FAH was twice the average normal level. Creatinine (Crn) is a small and freely filtered solute by the glomeruli of the kidney. Crn is produced from the break down of creatine in muscle. A reduced glomerular filtration rate (GFR) leads to retention of Crn in the blood. If we assume that Crn is produced at a constant rate in an individual, then a 50 percent reduction in GFR results in proximate doubling of the plasma Crn concentration [7].

Evyn developed hypernatremia, hyperchloremia, hyperkalemia, hyperphosphatemia, and hypermagnesiumemia following his admission to the hospital. His blood osmolality increased significantly (Table 19). These data indicate that Evyn's suffered from infections and kidney damage.

7. The likely causes of Evyn's intracranial bleeding and bleeding in other locations

Evyn was pronounced dead in Potter County, Texas on April 22, 2007. LifeGift harvested his organs for donation at about 1400 on April 23rd. He was given 3600 units of heparin IV prior to removing his organs to prevent the coagulation of the blood in organs and tissues. Evyn's weight prior to harvesting his organs was 8.7 kg and his weight after removing the organs and blood was 7.285 kg (Section 5).

Dr. Thomas R. Parsons performed the autopsy on Evyn's body at 0930 on April 24, 2007 (Case # 07-0256). He observed bleeding in the soft tissues outside the skull, intracranial bleeding, and optic nerve sheath hemorrhage (Table 21). He

alleged that Evyn's bleeding was caused by blunt trauma to the head.

A CT scan taken at 50 minutes following Evyn's admission to the hospital showed increased attenuation along the falx that raised the suspicion for the presence of subdural bleeding. However, the autopsy revealed a significant bleeding outside Evyn's skull and intracranially (Table 21). These data indicate that most of Evyn's bleeding occurred in the hospital. The likely causes of Evyn's bleeding were infections, liver damage, vitamin K deficiency, and the large dose of heparin given prior to harvesting his organs.

Table 21. Locations of bleeding observed on Evyn's CT head scan taken at 50 minutes post his admission to the hospital and at autopsy

Exam type and time	Findings
CT-scan head exam 4/21/07 (1756)	<ul style="list-style-type: none"> Increased attenuation along the falx that may represent a subdural hematoma or possibly be secondary to the decreased density in the adjacent brain parenchyma.
Autopsy 4/24/07 (0930)	<ul style="list-style-type: none"> Reflecting the scalp demonstrated abundant soft tissue hemorrhage overlying a marked widening of the sagittal suture in the midline. Removal the bony calvarium demonstrated abundant epidural hemorrhage associated with the widened sagittal suture. The epidural hemorrhage extended to the subgaleal soft tissues. Reflecting the dura demonstrated a scant subdural hemorrhage, which was accentuated in the midline. Examination of the base of the skull demonstrated marked hemorrhage at the optic nerve sheath.

7.1 Infections cause clotting problems and bleeding

Evyn was suffering from bacterial infections (*Streptococcus pneumoniae* and *Haemophilus influenzae*) and septicemia. His blood sample taken at about 19 hours FAH for bacterial culture showed a heavy growth of *S. pneumoniae* and *H. influenzae* (Table 10). Gram stain study of his sputum revealed the presence of a significant growth of Gram-positive cocci and the presence of a significant number of white blood cells.

A blood sample analyzed at 20 minutes following Evyn's admission to the hospital (FAH) revealed an elevated white blood cell count (WBC) of $21.8 \times 10^3/\mu\text{L}$. His white blood cells and neutrophils (segmented and band) counts stayed elevated at about 18 hours FAH. He was treated with antibiotics (ciprofloxacin and tobramycin) and his WBC returned to a normal level at 26 hours FAH.

Evyn's platelet count was within the normal range at admission but it was reduced by 40% at 26 hours FAH (Tables 11, 12). It indicates that he suffered from disseminated intravascular coagulation (DIC) due to septicemia.

Septicemia is frequently accompanied by changes in the plasmatic as well as cellular coagulation systems and by microclot formation. The activation of coagulation by endotoxin is mediated by synthesis of tissue factor by monocytes and endothelial cells.

Some microorganisms have specific properties, which affect individual components of hemostasis and thus increase their virulence. Furthermore, thrombocytopenia, thrombocytopathy and endothelial cell damage caused by a direct effect of the toxic agents contribute to the bleeding diathesis [39, 40].

Levi stated that DIC occurs frequently in septic patients and associated with increased mortality. Organ dysfunction is also a common sequela that is strongly correlated with DIC. Cytokines released early in the course of sepsis stimulate a procoagulant state that causes development of intravascular fibrin deposition. In a later stage of DIC, bleeding may occur in parallel because of consumption of clotting factors and inhibitors [41].

Voves *et al.* evaluated the score for DIC published by the International Society for Thrombosis and Haemostasis (ISTH) in a 32 patients suffering from severe sepsis and 8 patients with septic shock. Fibrin monomer and D-dimer were chosen as fibrin-related markers (FRM), respectively. DIC scores for nonsurvivors ($n = 13$) as well as for septic shock patients were higher ($P < 0.04$) compared with survivors and patients with severe sepsis, respectively.

Using fibrin monomer and D-dimer, 30 and 25% of patients suffered from overt DIC. Overt DIC was associated with significantly elevated thrombin-antithrombin complexes and plasminogen activator inhibitor type-1 levels as well as with significantly lower factor VII clotting activity. Patients with overt DIC had a significantly higher risk of death and of developing septic shock. Since more than 95% of the sepsis patients had elevated FRM, the DIC score was strongly dependent on prolongation of the prothrombin time and platelet counts [42].

Furthermore, Gando *et al.* evaluated 19 patients with the diagnosis of severe sepsis or septic shock and 9 control patients to obtain systematic information on the extrinsic coagulation pathway, as well as to investigate the time course of the coagulation abnormalities in sepsis. Tissue factor antigen concentration (tissue factor antigen), prothrombin fragment F1+2, thrombin antithrombin III complex, fibrinopeptide A, D-dimer, and antithrombin III concentrations were measured on the day of diagnosis of severe sepsis and septic shock, and on days 1, 2, 3, and 4 after diagnosis [43].

They found that the concentrations of tissue factor antigen, prothrombin fragment F1+2, fibrinopeptide A, and D-dimer were significantly increased in patients with severe sepsis and septic shock compared with control subjects. Significantly, low antithrombin III concentrations were observed in the septic patient groups compared with control subjects. Significant correlations were noted between tissue factor antigen and the disseminated intravascular coagulation score ($r^2=0.236$, $p<0.0001$) and the number of dysfunctioning organs ($r^2=0.229$, $p=0.035$) [43].

7.2 Vitamin K deficiency has led to intracranial bleeding in children

Evyn was very sick during the 6 days prior to his respiratory arrest. He was not eating well, vomited a lot and had diarrhea. He had lost 200 g during the 1.5 months prior to his death on April 22, 2007. It is expected that he gains about 692 g during that period based on his previous weight gain rate of 15.72

g/day. His gain rate during the first 12.5 of his life was 15.72 g (Table 22).

Furthermore, Evyn suffered from respiratory infections and bronchitis on several occasions during the six months prior to his death and treated with antibiotics and corticosteroid. Evyn's prothrombin time (PT) and international normalized ratio (INR) were elevated at 2 hours FAH. They also increased by 11-13% of their initial values at 18 hours FAH (Table 15). PT measures clotting factors II, V, VII, X and fibrinogen and it is elevated in children with vitamin K deficiency.

Vitamin K controls the formation of coagulation factors II (prothrombin), VII (proconvertin), IX (Christmas factor), and X (Stuart factor) in the liver. Other coagulation factors that depend on vitamin K are proteins C, S, and Z. Furthermore; two bone matrix proteins necessary for normal bone metabolism are vitamin K-dependent.

These vitamin K-dependent proteins contain the amino acid γ -carboxyglutamic acid and the carboxyl groups of the glutamic acid residues that provide the vitamin-K-dependent proteins with characteristic calcium and phospholipid binding properties. Vitamin K deficiency leads to the production of abnormal vitamin K-dependent factors, which lack gamma-carboxy glutamic acid residues in the NH₂-terminal part of their molecules [44-49].

In humans, the body does not synthesize the 1, 4 naphthoquinone nucleus of vitamin K and gets it from food. In addition, the bacteria in the intestinal tract synthesize vitamin K and can supply part of the vitamin K requirement. Signification reduction of food intake occurred in serious illness and the treatment with high therapeutic doses of antibiotics for a significant time can lead to vitamin K deficiency and intracranial bleeding in children. [44-46, 50-53].

In addition, septicemia originating in the intestinal tract was frequently associated with the development of vitamin K deficiency. Besides changes in the intestinal flora, a reduction in oral food intake and the presence of a methylthiotetrazole group in the structure of the administered antibiotics were also found to play a crucial role in causing vitamin K deficiency [52].

De Montalembert evaluated the medical records of 43 cytic fibrosis individuals and found a significant correlation between PIVKA-II concentrations and the administration of antibiotics in these individuals [53].

In addition, Bhat and Deshmukh conducted a prospective non-randomized study on children receiving antibiotic therapy. Coagulation abnormalities were seen in children with malnutrition, receiving prolonged course of antibiotics, and in children who were critically ill in intensive care. Inhibition of intestinal microorganisms by antibiotics was thought to be a likely explanation of this phenomenon [51].

Aydinli *et al.* conducted a retrospective study included 11 babies between 30 and 119 days of age, who developed bleeding due to vitamin K deficiency. The localizations of the intracranial haemorrhage were as follows: intracerebral (91%), subarachnoid (46%), subdural (27%), and intraventricular (27%). The presenting complaints were seizures (91%), drowsiness (82%), poor sucking (64%), vomiting (46%), fever (46%), pallor (46%), acute diarrhea (27%), irritability and high-

pitched cry (18%). On examination, tense or bulging fontanelle (73%), anisocoria (36%), weak neonatal reflexes (18%), cyanoses (18%) were the most frequent findings [54].

In addition, Chaou *et al.* reported late-onset intracranial hemorrhage related to vitamin K deficiency in 32 breast-fed infants (1/2 to 6 months of age). Computerized tomography showed mild to severe intracranial hemorrhage. Most (90.6%) had subarachnoid hemorrhage, either alone or in combination with subdural hemorrhage (37.5%), parenchymal hemorrhage (31.3%), or intraventricular hemorrhage (12.5) [55].

Furthermore, Choo *et al.* conducted a retrospective study of 42 infants who were admitted to the hospital for spontaneous bleeding and prolonged prothrombin and partial thromboplastin times. Subdural hemorrhage was the most common form of intracranial haemorrhage, followed by subarachnoid hemorrhage. None of the infants had bleeding due to inherited coagulopathy or disseminated intravascular coagulation [56].

Table 22. Evyn's weight, length, and head circumference measurements

Date	Age (days)	Weight (g)	Length (cm)	Head circum. (cm)
02/23/06	Birth	2925 (25-50) ¹	51.4 (75-90) ¹	33.7 (50) ¹
04/10/06	46	3090	52.7	35.7
04/26/06	62	4000	58.4	37.5
06/25/06	122	5273 (3rd)	61.6 (25)	40.4
08/25/06	183	6454 (10)	66.0 (25-50)	41.6 (10)
11/28/06	278	7800 (3-5)	71.2 (50)	43.5 (10)
02/28/07	370	8300 (3 rd)	73.7 (50)	45.8 (25)
03/8/07	378	8900	--- ²	---
04/22/07	422	8700 (<3 rd)	---	---
04/23/07	Autopsy	-	79	46

¹ Percentile

² Not measured

8. The likely causes of the brain edema, hypoxic change in the brain, and widening of the sagittal suture observed in Evyn's case

Evyn's organs were harvested on April 23, 207 and Dr. Thomas R. Parsons performed the autopsy on Evyn's body on April 24. He found severe brain edema and herniation of the brain, intracranial bleeding, and widening of the sagittal suture (Table 23). He also examined the H & E stained tissue sections of brain microscopically and observed edema and hypoxic change. He alleged that the abnormal changes observed in Evyn's brain and widening of the suture caused by blunt trauma to the head.

The clinical data indicate that most of the brain edema, herniation, and widening of the sagittal suture occurred following Evyn's admission to the hospital. A CT scan taken at 50 minutes following Evyn's admission to the hospital did not show severe edema, herniation of the brain, or widening of the sagittal suture (Table 23). These lesions were caused by hypoxia, medications, bleeding, and increased intracranial pressure (ICP) as described below.

Evyn was suffering from metabolic acidosis at the time of admission to the hospital and treated with high doses of sodium bicarbonate. He had a blood pH of 7.24 and the treatment with sodium bicarbonate IV raised his blood pH to a critically high level of 7.60 (Table 13). The treatment with high doses of sodium bicarbonate has caused anoxia and brain edema in children [7, 44, 57, 58]. Fauci *et al.* reported that alkalinization of the blood with sodium bicarbonate increases the avidity of hemoglobin to bind oxygen, thus impairing the release of oxygen in peripheral tissues [7].

I examined the H & E stained tissue sections of Evyn's brain microscopically and also observed hypoxic changes. Hypoxia and bleeding cause brain edema, necrosis, and inflammation in the brain. For example, Stys stated that the white matter of the brain and spinal cord is susceptible to anoxia and ischemia. Myelinated axons of the CNS are critically dependent on a continuous supply of energy largely generated through oxidative phosphorylation.

Anoxia and ischemia lead to rapid energy depletion, failure of the Na⁽⁺⁾-K⁽⁺⁾-ATPase, and accumulation of axoplasmic Na⁺ through non-inactivating Na⁺ channels, with concentrations approaching 100 mmol/L after 60 minutes of anoxia. Ischemia and anoxia also cause severe K⁺ depletion that results in large membrane depolarization. In addition, they lead to excessive accumulation of Ca²⁺ that activates various Ca⁽²⁺⁾-dependent enzymes, such as calpain, phospholipases, and protein kinase C, resulting in irreversible injury [59].

Stys *et al.* also evaluated the mechanisms of anoxic injury using the in vitro rat optic nerve. Functional integrity of the nerves was monitored electrophysiologically by quantitatively measuring the area under the compound action potential. It recovered to 33.5 +/- 9.3% of control after a standard 60 min anoxic insult [60].

Their study revealed that anoxia caused rapid depletion of ATP and membrane depolarization leading to Na⁺ influx through incompletely inactivated Na⁺ channels. The resulting rise in the intracellular [Na⁺] coupled with membrane depolarization caused damaging levels of Ca²⁺ to be admitted into the intracellular compartment. It entered the cell through reverse operation of the Na⁽⁺⁾-Ca²⁺ exchanger [60].

Dolinak *et al.* evaluated the relationship between hypoxia and the incidence of axonal injury in the brains of individuals died from cardio-respiratory arrest (17 cases) and status epilepticus (12 cases). Axonal damage was seen in 9/17 and 7/12 of the cases with cardiac arrest and status epilepticus, respectively, in most of whom there was also evidence of raised intracranial pressure (ICP). It is concluded that the great majority of axonal damage identified in cases dying after cardiac arrest and status epilepticus can be attributed to raised ICP and the vascular complications of internal herniation. In

many cases there was an increase in expression of neuronal beta amyloid precursor protein [61].

In addition, Kaur *et al.* studied material comprised sections from 28 brains showing evidence of cerebral hypoxia with no history of head injury to assess the possible role of hypoxia in the formation of axonal bulbs. These were subjected to microwave antigen retrieval and immunohistochemistry using monoclonal antibodies to beta amyloid precursor protein (beta APP), glial fibrillary acid protein (GFAP), and CD68-PGM1. They found positive staining for beta APP present in 12 of 28 cases of hypoxia without history of head injury. They stated that the presence of axonal bulbs cannot necessarily be attributed to shearing forces alone [62].

Furthermore, Niess *et al.* examined 450 non-selected human brains of individuals died from different causes to estimate the overall incidence of diffuse axonal injury (DAI). Samples from two brain areas (pons and cerebrum) were immunostained for beta-amyloid-precursor-protein (betaAPP), and axonal damage was assessed microscopically.

Axonal injury was detected in 12% of all cases, but only one third had a history of traumatic brain injury. The majority of the positive cases were associated with drug intoxication, chiefly due to opiates. They stated that various causes may produce diffuse axonal injury and traumatic brain injury is not the only and probably not even the main cause of the observed neuropathological changes [63].

Evyn had intracranial bleeding and bleeding causes irritation and brain edema. For example, Mayer *et al.* performed paired consecutive CT and ^{99m}Tc-hexamethylpropylenamine oxime single-photon emission computed tomography (SPECT) scans during the acute (mean, 18 hours) and subacute (72 hours) phase of intracerebral hemorrhage (ICH) in 23 individuals.

Hematoma and edema volumes were traced and calculated from CT images. They found that the ICH volume (18 mL) did not change but the mean edema volume was increased by 36% (from 19 to 25 mL, $P < 0.0001$). Perilesional edema on CT always corresponded topographically with perfusion deficits on SPECT [64].

In addition, Mehdiratta *et al.* retrospectively reviewed prospectively-collected clinical and laboratory data from 23 consecutive individuals with acute spontaneous ICH. These individuals had a CT scan checked on admission and a follow-up CT scan 3 to 4 days afterward.

They measured hematoma and edema volumes on admission and follow-up scans, and calculated the relative edema volume to correct for hematoma volume. They used Spearman correlation coefficient to determine the association of various variables with relative perihematoma edema volume. They found that the median hematoma volume increased by approximately 28% from baseline to day 3 to 4. However, the relative edema volume almost doubled during this time period [65].

The bleeding and edema led to the increase in the ICP and widening the sagittal suture in Evyn's case. I reviewed the medical files of a 17-month-old child who developed separation of the coronal suture following his admission to the hospital due to increased intracranial pressure resulted from bleeding and edema [58]. Increased ICP due to brain edema and intracranial bleeding also caused a skull fracture in a case of 1.5-month-old infant [57].

Table 23. Progress of Evyn's brain edema following admission to the hospital

Exam type	Date & Time	Findings
CT scan	4/21/07 (1756)	• Diffusely decreased brain attenuation and diminished gray/white differentiation suggesting global anoxia.
Autopsy	Autopsy 4/24/07 (0930)	• Marked widening of the sagittal suture in the midline. • Severe edema of the brain • Marked herniation of the hippocampal unci and cerebellar tonsils.

9. The likely causes of the bruises and marks observed on Evyn's body at autopsy

Evyn was given 3600 units of heparin IV prior to harvesting his organs on April 23, 2007. Dr. Thomas R. Parsons performed the autopsy on Evyn's body on April 24th and observed 17 minor bruises and marks (Table 24). The autopsy was performed at 64 hours following Evyn's admission to the hospital. He alleged that these bruises and marks were caused by trauma.

The following clinical observations indicate that the likely causes of the bruises and marks observed on Evyn's body at autopsy were heparin, septicemia, vitamin K deficiency, and liver injuries. Evyn received 414 units of heparin/kg on April 23rd, which is 8.3 times the therapeutic dose. Heparin was given to prevent the coagulation of blood in tissues.

1) Parsons reported 17 bruises and marks on Evyn's body (Table 24). However, the treating physicians noted only 8 bruises at various stage of healing at the time of Evyn's admission to the hospital on April 21st. These include: One bruise to left ear; 5 round shaped bruises on the right flank; and 2 bruises on the left and right femoral areas. These observations indicate that at least 9 bruises and marks developed after Evyn's admission to the hospital.

2) No evidence of injury caused by trauma was noted on Evyn's head, face, neck, back, and genitalia at the time of his admission to the hospital. In addition, the CT scans of the head and spine taken on April 21st revealed no fracture.

3) Parsons examined the H & E stained sections of Evyn's skin (back and the posterior leg) microscopically and observed various degree of extravasation of red blood cells in the subcutaneous and adipose tissues. I also examined these sections of the skin and observed fresh bleeding, less than 24 hours old (Figures 1, 2).

4) The areas of ecchymosis bleeding observed on Evyn's inguinal areas were surrounding needle puncture marks (Table 24). The leakage of the blood from the needle puncture site indicates that Evyn's had blood coagulation problems. The bleeding in these areas was not present at the time of Evyn's admission at the hospital.

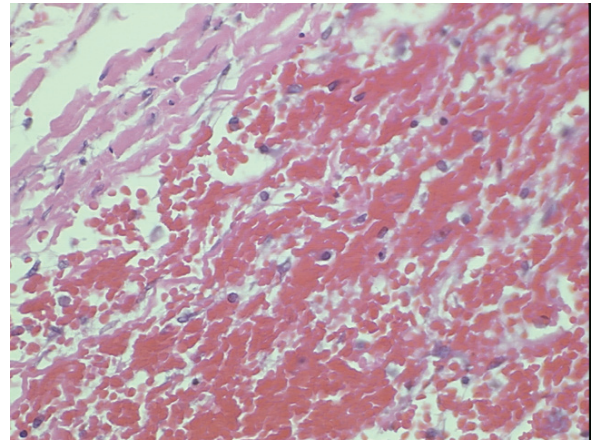
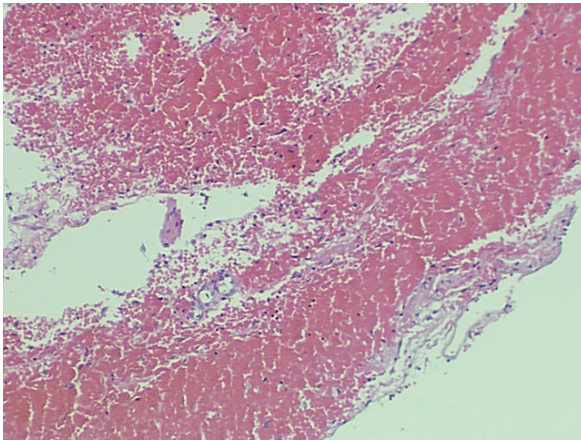


Figure 1. Shows the intensity of the bleeding in Evyn's subcutaneous tissue (H & E, x 25).

Figure 2. Shows intact red blood cell (fresh bleeding <24 hours old) in Evyn's subcutaneous tissue (H & E, x 63).

Table 24. Minor bruises and marks observed on Evyn's body at autopsy

Regions	Bruises and marks
Ear	<ul style="list-style-type: none"> • A purple-red contusion (0.8 x 0.3 cm) located over the helix of the left ear.
Chest	<ul style="list-style-type: none"> • A purple-blue contusion (1.5 x 1.2 cm) present over the right lateral chest just posterior of the midaxillary line. • A purple-blue contusion (0.8 x 0.5 cm) located over the left side of the chest just anterior to the midaxillary line. • A purple-red contusion (0.5 x 0.6 cm) found over the right side of the chest.
Back	<ul style="list-style-type: none"> • Overlying the back extending from side to side was an area of greenish suffusion of the skin extended 10 x 13 cm on the left side of the back and 8 x 13 cm on the right side of the back. • A purple-red contusion (1 x 0.5 cm) located over the lower thoracic back. Beneath this contusion was a similar appearing contusion (0.6 x 0.5 cm) and to the right of it was a 1.2 x 0.8 cm similar appearing contusion.
Sacral	<ul style="list-style-type: none"> • A purple-red contusion (1.5 x 1.2 cm) present over the sacral area.
Iliac	<ul style="list-style-type: none"> • A red discoloration (3.5 x 2.1 cm) present over the left posterior iliac area.
Inguinal areas	<ul style="list-style-type: none"> • Surrounding the needle puncture marks in the right inguinal area was an area of purple-blue ecchymosis measuring up 3 x 2.5 cm. • On the left side, there was an area of ecchymosis surrounding needle puncture marks measuring 2 x 2 cm. • Additional ecchymosis was surrounding needle puncture marks.
Hip	<ul style="list-style-type: none"> • A purple-brown contusion (3.9 x 1.3 cm) observed over the right side of the hip.
Thigh	<ul style="list-style-type: none"> • A purple-blue contusion (2 x 0.7 cm) and a purple-red contusion (2 x 0.6 cm) located over the posterior left thigh.

10. Vaccines given and their influence on Evyn's health

Evyn received 27 vaccines between the age of 2 and 12 months and developed health problems following receiving these vaccines. The severity of his health problems increased significantly following receiving vaccines at 6 months of age. He developed bronchitis and treated with antibiotics and corticosteroids (Table 25).

The treatment with corticosteroids led to immune suppression and increased Evyn's risk for viral, bacterial, and fungal infections. He developed viral infections, bronchitis, and thrombocytopenia. He was treated with antibiotics, antipyretics and corticosteroids. He developed fungal infection at the age of 11 months and treated with antifungal medication.

His fungal infection indicates that he was suffering from a significant immune depression. However, he was given six vaccines at the age of 12 months and some of these vaccines contain attenuated live viruses. Evyn suffered from respiratory arrest and died at the age of 14 months (Table 25). Clinical tests showed that he was suffering from bacterial infections (*Streptococcus pneumoniae* and *Haemophilus influenzae*) and septicemia.

Evyn had lost 200 g during the 1.5 months prior to his death on April 22, 2007. It is expected that he gains about 692 g during that period based on his previous weight gain rate of 15.72 g/day (Table 22). Evyn was very sick during the 6 days prior to his respiratory arrest. He was not eating well, vomited a lot, and had diarrhea.

Vaccines should not be given to sick children, suffering from immune suppression, and/or treated with corticosteroids. It has been reported that sick children have failed to respond adequately to vaccines as compared to healthy children. For example, Krober *et al.* examined 47 infants with colds and 51 well infants at the age of 15 to 18 months, who received the standard measles-mumps-rubella (MMR) vaccine, for their response to develop the measles antibody.

Pre-vaccination serum samples were obtained prior to vaccine administration and post-vaccination serum samples were obtained 6 to 8 weeks later. Measles antibody was measured in these serum samples by an indirect fluorescein-tagged antibody test. Ten (21%) of 47 infants with colds failed

to develop the measles antibody, while only one (2%) of 51 well infants failed to develop an antibody [66].

I reviewed the medical records of a 15 months old child who developed a cute pancreatic infection and died at 3 months following receiving her measles, mumps, rubella (MMR) and varicella vaccines. She was suffering from chronic immune depression, fungal infection, poor appetite, and poor weight gain at the time of vaccination [67].

Vaccines given to Evyn contain various antigens, heavy metals, antibiotics, preservatives, and attenuated live viruses [11, 12, 67- 69]. Additive and synergistic actions among these components in causing serious health problems can occur even in healthy children and adults. I have evaluated cases of infants and a toddler who died as a result of adverse reactions to vaccines [44, 67, 68].

I have also evaluated cases of children and adult who developed serious health problems from vaccines [70-74]. One of these cases was a two months old infant who received 7 vaccines while he was ill and suffered from developmental delay, anemia, subdural bleeding, and femoral abnormalities. His head circumference (HC) was 38.7 cm on the day of vaccination and it reduced to 37.3 cm at 32 days post vaccination. The baby's HC growth rate during the 2 months prior to vaccination was 2.8 cm/month [72].

In addition, I evaluated a case of triplets who were vaccinated with DTaP, IPV, Hib, and PCV vaccines at the age of 2-2.5 months and developed serious illnesses at two weeks following vaccination. The first baby (female) suffered from apnea, metabolic acidosis, seizure, infection, intracranial and retinal bleeding, and skull fracture. The second baby (male) developed respiratory tract and eye infection, severe anemia, bleeding, and skull fracture. The third baby (male) had severe anemia and skull fracture [70].

Vaccines have caused serious illnesses and even death in some healthy children. For example, Zhou *et al.* analyzed reports on the adverse events of vaccines reported to the USA Vaccine Adverse Event Reporting System (VAERS) from January 1, 1991, through December 31, 2001. VAERS received 128,717 reports. They found that a total of 14.2% of all reports described serious adverse events, which by regulatory definition include death, life-threatening illness, hospitalization or prolongation of hospitalization, or permanent disability [75].

Evyn received 27 vaccines during 10 months and incidents of serious illnesses and death have been reported in children received a fewer vaccines than Evyn. For example, Wise *et al.* evaluated 4154 reports of events occurring after vaccination with 7-valent pneumococcal conjugate vaccine (PCV) in the United States during the first two years after licensure of PCV. Reports studied were for children younger than 18 years and vaccinated with PCV. These reports were obtained from the Vaccine Adverse Event Reporting System (VAERS) database [76].

The most frequently reported symptoms and signs included fever, injection site reactions, fussiness, rashes, and urticaria. Serious events were described in 14.6% of reports. There were 117 deaths, 23 reports of positive rechallenges, and 34 cases of invasive pneumococcal infections possibly representing vaccine failure. Immune-mediated events occurred in 31.3% of reports. Thrombocytopenia developed in 14 children, serum

sickness in 6 children, and 14 children suffered from anaphylactic or anaphylactoid reactions. Neurologic symptoms occurred in 38% of reports. Seizures described in 393 reports included 94 febrile seizures [76].

In addition, reports sent to VAERS, concerning infant immunization against pertussis between January 1, 1995 and June 30, 1998 were analyzed. During the study period, there were 285 reports involving death, 971 non-fatal serious reports (defined as events involving initial hospitalization, prolongation of hospitalization, life-threatening illness, or permanent disability), and 4,514 less serious reports after immunization with any pertussis-containing vaccine [77].

Niu *et al.* evaluated reports of neonatal deaths (aged 0-28 days) after hepatitis B (HepB) immunization reported to the National Vaccine Adverse Event Reporting System (VAERS) January 1, 1991, through October 5, 1998. They identified 18 deaths (8 boys, 9 girls, 1 unclassified). The mean birth weight of the neonates (n = 15) was 3034 g (range, 1828-4678 g). The mean age of the infants at vaccination was 12 days. The median time from vaccination to onset of symptoms was 2 days and the median time from symptoms to death was 0 days (range, 0-15 days). The causes of death for the 15 autopsied cases were sudden infant death syndrome for 12 and infection for 3 [78].

It has been reported that MMR vaccine caused acute and chronic illnesses in some children, when given alone or concurrently with other vaccines. These include malaise, sore throat, cough, rhinitis, headache, dizziness, fever (101-102.9 °F), rash, nausea, vomiting, diarrhea, fever, regional lymphadenopathy, parotitis, orchitis, nerve deafness, vasculitis, otitis media, hearing loss, conjunctivitis, aseptic meningitis, measles, thrombocytopenia, allergy, and anaphylaxis [11, 79-84].

Cases of aseptic meningitis associated with measles, mumps, and rubella vaccine were sought in thirteen UK health districts following a reported cluster in Nottingham, which suggested a risk of 1 in 4,000 doses. Cases were ascertained by obtaining vaccination records of children with aseptic meningitis diagnosed from cerebrospinal fluid samples submitted to Public Health Laboratories or discharged from hospital with a diagnosis of viral meningitis.

Both methods identified vaccination 15-35 days before onset as a significant risk factor and therefore indicative of a causal association. With both, half the aseptic meningitis cases identified in children aged 12-24 months were vaccine-associated with onset 15-35 days after vaccine. This study confirmed that the true risk was substantially higher than suggested by case reports from pediatricians, probably about 1 in 11,000 doses [82].

Furthermore, in Japan, at least 311 meningitis cases suspected to be vaccine-related were identified among 630,157 recipients of the measles-mumps-rubella trivalent (MMR) vaccine. These cases were identified based on the notification of cases and the testing of mumps viruses isolated from cerebrospinal fluid for their relatedness to the vaccine by nucleotide sequence analysis [83].

Table 25. Vaccines given to Evyn and list of illnesses and medications

Date	Age (m)	Health problems, vaccines, and medications
4/26/06	2	Symptoms: Low weight, fussy, and spitted up formula Treatments: Zantac and Reglan Vaccines: Hib, Prevnar, and Pediarix (5 vaccines) ¹
6/25/06	4	Symptoms: Low weight, elevated lymphocyte count, and infections. Vaccines: Hib, Prevnar, and Pediarix (5 vaccines) ¹
8/25	6	Vaccines: Hib, Prevnar, and Pediarix (5 vaccines) ¹
10/04/06	7.4	Symptoms: Bad cough. Throat culture was positive for Streptococcus. Treatment: antibiotic (Omnicef)
10/12/06	7.6	Illness and symptoms: Bronchitis, fever, and cough. Treatment: Albuterol and Dep medrol (Methylprednisolone)
10/18/06	7.8	Symptoms: Fever, cough, thrombocytopena, and lost weight. Hospitalized for 3 days. Treatments: Albuterol and Dep medrol (Methylprednisolone)
1/04/07	10.4	Symptoms and illness: Bronchitis, fever, cough, congested, reduced appetite. Treatments: Albuterol and Dep medrol (Methylprednisolone)
1/28/07	11	Symptoms and illness: Trouble breathing, vomiting, fungal infection. Treatment: Diflucan (antifungal)
2/28/07	12	Symptoms: Fever, cough, chest was congested. Treatment: Tylenol Vaccines: Hep A, Prevnar, and Proquad (4 vaccines) ²
3/08/07	12.5	Symptoms and illness: Fever, acute viral syndrome.
4/09/07	13.5	Symptoms and illness: Tonsillitis, bronchitis, coughing, runny nose. Treatment: Motrin and Tylenol.
4/20/07	14	Symptoms: Vomiting
4/21/07	14	Symptoms and illness: Vomiting, diarrhea, respiratory arrest, acidosis, infections, anemia, elevated liver enzymes.

¹Pediarix: Diphtheria and Tetanus Toxoids and Acellular Pertussis Adsorbed, Hepatitis B (Recombinant) and Inactivated Poliovirus Vaccine Combined.

²Proquad: measles, mumps, rubella, and chickenpox vaccines.

11. Conclusions

The clinical data and medical studies presented in this report clearly show that Evyn suffered from respiratory arrest on April 21, 2007 as a result of bacterial infections (*Streptococcus pneumoniae* and *Haemophilus influenzae*), pneumonia, and septicemia. Bacterial infections are confirmed by bacterial blood culture, white blood cell and differential counts, chest CT scan exam, urine analysis, and response to antibiotics

The likely causes of Evyn's bleeding were infections and septicemias, liver damage, vitamin K deficiency, and the large dose of heparin given prior to harvesting his organs. Evyn had liver problems and the majority of the blood clotting factors is synthesized in the liver. Evyn's prothrombin time (PT) and international normalized ratio (INR) were elevated.

Evyn was sick for several days and lost weight during the 1.5 months prior to his death. Evyn suffered from bronchitis and treated with antibiotics and corticosteroids. A significant reduction of food intake occurred in serious illness and the treatment with high therapeutic doses of antibiotics for a significant time have led to vitamin K deficiency and intracranial bleeding in children.

The dose of heparin given to Evyn (3600 units) is 8.3 times the therapeutic dose given to children. Examination of the H & E stained section of the skin microscopically revealed fresh bleeding, less than 24 hours old. The autopsy was performed at 64 hours following Evyn's admission to the hospital.

Most of Evyn's brain edema, herniation, and widening of the sagittal suture occurred following Evyn's admission to the hospital as shown by Evyn's CT head exams. They were caused by hypoxia, medications, bleeding, and increased intracranial pressure (ICP). Evyn treated with high doses of sodium bicarbonate IV in the hospital that raised his blood pH from 7.24 to 7.60. The treatment with high doses of sodium bicarbonate has caused anoxia and brain edema in children.

The likely causes of the bruises and marks observed on Evyn's body at autopsy were septicemia, vitamin K deficiency, liver injuries, and heparin. The medical examiner (ME) observed 17 bruises and marks on Evyn's body. However, the treating physicians noted only 8 bruises at various stage of healing at the time of Evyn's admission to the hospital. These observations indicate that at least 9 bruises and marks developed after Evyn's admission to the hospital.

Vaccines and the treatment with corticosteroids caused Evyn's health problems and immune depression that increased his risk for infections. The severity of Evyn's health problems increased significantly following receiving vaccines at 6 months of age. He developed bronchitis and treated with antibiotics and corticosteroids.

Evyn developed fungal infection at the age of 11 months and treated with antifungal medication. He received six vaccines at the age of 12 months while he was suffering from immune depression and some of these vaccines contain attenuated live viruses. Vaccines should not be given to sick children and children treated with corticosteroids.

The ME's investigation is incomplete and his allegation that Evyn's death was caused by blunt trauma is not supported by the clinical and medical studies presented in this report. He did not exam Evyn's lung, heart, liver, and other infected tissues grossly or microscopically. In addition, he did not consider infections, septicemia, heparin, and the adverse reactions of vaccines and medications in causing Evyn's health problems and death.

References

- [1] Chasity Michelle Burrier's medical records (2/23-25/2006). Northwest Texas Hospital, 1501 S Coulter Amarillo, Texas 79175, Potter County.
- [2] Evyn William Vaughn's medical records (2/23-3/10/2006). Northwest Texas Healthcare System, 1501 S Coulter. Amarillo, Texas 79175, Potter County.
- [3] Evyn William Vaughn's medical records (4/10/2006-4/9/2007). Northwest Texas Hospital, 1501 S Coulter Amarillo, Texas 79175, Potter County.

- [4] Michael Wayne Garrard's letter to Al-Bayati MA, January 30, 2008.
- [5] EMS's report on Evyn Vaughn (incident # 16488). Amarillo Medical Services. April 21, 2007.
- [6] Evyn William Vaughn's medical records (4/21-23/2007). Northwest Texas Hospital, 1501 S Coulter Amarillo, Texas 79175, Potter County.
- [7] Fauci AS, Braunwald E, Isslbacher KJ, Wilson, JD, Martin JB, Kasper DL, Hauser SL, Longo DL. Harrison's Principles of Internal Medicine. McGraw-Hill Companies, Inc. New York USA, ed. 14, 1998.
- [8] Al-Bayati MA. Analysis of causes that led to toddler Steven Young's respiratory arrest, intracranial and retinal bleeding, bronchopneumonia, peritonitis, and death. *Medical Veritas* 2008; 5(2):1775–96.
- [9] Baylor Liver Transplant Team's operative report on Evyn Vaughn (# 570125). April 23, 2007. Lifegift No. 6020566. Department of Surgery. Baylor College of Medicine. Houston, TX.
- [10] Parsons RT. Autopsy report in the case of Evyn Vaughn. Potter County, Texas, Case # 07-0256. Texas Tech University Health Sciences Center, Division of Forensic Pathology. 4434 South Loop 289. Lubbock, TX 79414. April 24, 2007.
- [11] Physicians' Desk Reference, Edition 53, 1999. Medical Economics Company, Inc, Montavale, NJ, USA.
- [12] Physicians' Desk Reference, Edition 57, 2003. Thomson PDR, Montavale, NJ, USA.
- [13] Nascimento-Carvalho CM. Etiology of childhood community acquired pneumonia and its implications for vaccination. *Braz J Infect Dis*. 2001 Apr;5(2):87–97. Epub 2001 Aug 3.
- [14] McCracken GH Jr. Etiology and treatment of pneumonia. *Pediatr Infect Dis J*. 2000 Apr;19(4):373–7.
- [15] Rudan I, Boschi-Pinto C, Biloglav Z, Mulholland K, Campbell H. Epidemiology and etiology of childhood pneumonia. *Bull World Health Organ*. 2008 May;86(5):408–16.
- [16] Burgner D, Richmond P. The burden of pneumonia in children: an Australian perspective. *Paediatr Respir Rev*. 2005 Jun;6(2):94–100.
- [17] Sung RY, Cheng AF, Chan RC, Tam JS, Oppenheimer SJ. Epidemiology and etiology of pneumonia in children in Hong Kong. *Clin Infect Dis*. 1993 Nov;17(5):894–6.
- [18] Hsieh YC, Lee WS, Shao PL, Chang LY, Huang LM. The transforming *Streptococcus pneumoniae* in the 21st century. *Chang Gung Med J*. 2008 Mar-Apr;31(2):117–24.
- [19] Hortal M, Suarez A, Deleon C, Estevan M, Mogdasy MC, Russi JC, Contera M, Meny M. Etiology and severity of community acquired pneumonia in children from Uruguay: a 4-year study. *Rev Inst Med Trop Sao Paulo*. 1994 May-Jun;36(3):255–64.
- [20] Espínola Docio B, Casado Flores J, de la Calle Cabrera T, López Guinea A, Serrano González A. Pleural effusion in children with pneumonia: A study of 63 cases. *An Pediatr (Barc)*. 2008 Sep;69(3):210–4.
- [21] Yao KH, Yang YH. *Streptococcus pneumoniae* diseases in Chinese children: past, present and future. *Vaccine*. 2008 Aug 18;26(35):4425–33. Epub 2008 Jul 3.
- [22] McCluskey J, Dowson CG, Mitchell TJ. The use of microarray technology for the analysis of *streptococcus pneumoniae*. *Comp Funct Genomics*. 2002;3(4):366–8.
- [23] Leelaramee A, Dhiraputra C, Hunnangkul S. Severe pneumococcal infection at a Thai hospital. *Int J Infect Dis*. 1999 Spring;3(3):147–52.
- [24] Farha T, Thomson AH. The burden of pneumonia in children in the developed world. *Paediatr Respir Rev*. 2005 Jun;6(2):76–82.
- [25] Greenwood B. The epidemiology of pneumococcal infection in children in the developing world. *Philos Trans R Soc Lond B Biol Sci*. 1999 Apr 29;354(1384):777–85.
- [26] Funkhouser A, Steinhoff MC, Ward J. *Haemophilus influenzae* disease and immunization in developing countries. *Rev Infect Dis*. 1991 May-Jun;13 Suppl 6:S542–54.
- [27] Panteghini M, Bonetti G, Pagani F, Stefani F, Giubbini R, Cuccia C. Measurement of troponin I 48 h after admission as a tool to rule out impaired left ventricular function in patients with a first myocardial infarction. *Clin Chem Lab Med*. 2005;43(8):848–54.
- [28] Takala J, Ruokonen E. Oxygen transport in septic shock. *Schweiz Med Wochenschr*. 1992 May 16;122(20):776–9.
- [29] Oliveira NS, Silva VR, Castelo JS, Elias-Neto J, Pereira FE, Carvalho WB. Serum level of cardiac troponin I in pediatric patients with sepsis or septic shock. *Pediatr Crit Care Med*. 2008 Jul;9(4):414–7.
- [30] Tzivoni D, Koukoui D, Guetta V, Novack L, Cowing G; CASTEMI Study Investigators. Comparison of Troponin T to creatine kinase and to radionuclide cardiac imaging infarct size in patients with ST-elevation myocardial infarction undergoing primary angioplasty. *Am J Cardiol*. 2008 Mar 15;101(6):753–7. Epub 2008 Jan 14.
- [31] McMahon CJ, Ayres N, Pignatelli RH, Franklin W, Vargo TA, Bricker JT, El-Said HG. Echocardiographic presentations of endocarditis, and risk factors for rupture of a sinus of Valsalva in childhood. *Cardiol Young*. 2003 Apr;13(2):168–72.
- [32] Ishiwada N, Niwa K, Tateno S, Yoshinaga M, Terai M, Nakazawa M. Pneumococcal endocarditis in children: a nationwide survey in Japan. *Int J Cardiol*. 2008 Jan 24;123(3):298–301. Epub 2007 Mar 23.
- [33] Cabezuolo Huerta G, Jiménez-Busselo MT, Frontera-Izquierdo P. Acute purulent pericarditis in childhood. *An Esp Pediatr*. 1986 Mar;24(3):171–6.
- [34] Murillo Vallés M, Cañadas Palazón S, Domínguez Sampedro P, Soler Palacin P, Bonjoch Mari C, Roqueta Mas J. Pneumococcal endocarditis in a previously healthy 17-month-old boy. *An Pediatr (Barc)*. 2007 Jun;66(6):615–8.
- [35] Spapen H. Liver perfusion in sepsis, septic shock, and multiorgan failure. *Anat Rec (Hoboken)*. 2008 Jun;291(6):714–20.
- [36] Koskinas J, Gomatos IP, Tiniakos DG, Memos N, Boutsikou M, Garatzioti A, Archimandritis A, Betrosian A. Liver histology in ICU patients dying from sepsis: a clinico-pathological study. *World J Gastroenterol*. 2008 Mar 7; 14(9):1389–93.
- [37] Sakorafas GH, Tsiotos GG, Sarr MG. Ischemia/Reperfusion-Induced pancreatitis. *Dig Surg*. 2000;17(1):3–14.
- [38] Zhou ZG, Chen YD. Influencing factors of pancreatic microcirculatory impairment in acute pancreatitis. *World J Gastroenterol*. 2002 Jun; 8(3):406–12.
- [39] Müller-Berghaus G. Sepsis and blood coagulation. *Behring Inst Mitt*. 1986 Feb;(79):131–41.
- [40] Hudecek J, Paceková M, Chudej J, Kubisz P. Infection and hemostasis. *Vnitr Lek*. 2004 Jun;50(6):453–61.
- [41] Levi M. Pathogenesis and treatment of disseminated intravascular coagulation in the septic patient. *J Crit Care*. 2001 Dec;16(4):167–77.
- [42] Voves C, Wuillemin WA, Zeerleder S. International Society on Thrombosis and Haemostasis score for overt disseminated intravascular coagulation predicts organ dysfunction and fatality in sepsis patients. *Blood Coagul Fibrinolysis*. 2006 Sep;17(6):445–51.
- [43] Gando S, Nanzaki S, Sasaki S, Aoi K, Kemmotsu O. Activation of the extrinsic coagulation pathway in patients with severe sepsis and septic shock. *Crit Care Med*. 1998 Dec;26(12):2005–9.
- [44] Al-Bayati MA. Analysis of Causes That Led to Baby Lucas Alejandro Mullenax-Mendez's Cardiac Arrest and Death in August-September of 2002. *Medical Veritas*, 2004; (1):45–63.
- [45] Al-Bayati MA. Analysis of causes that led to bleeding, cardiac arrest, and death in the case of baby Nadine. *Medical Veritas*, 2006; 3(2): 997–1012.
- [46] The Merck Manual of Diagnosis and Therapy. Editors Beets MH and Berkow R, 17th ed., 1999. Published by Merck Research Laboratories, Whitehouse Station, N.J.
- [47] Widdershoven J, Labert W, Motohara K, *et al*. Plasma concentrations of vitamin K1 and PIVKA-II in bottle-fed and breast-fed infants with and without vitamin K prophylaxis at birth. *European Journal of Pediatrics*. 148:139–42, 1988.
- [48] Sutor AH, von Kries R, Cornelissen EA, McNinch AW, Andrew M. Vitamin K deficiency bleeding (VKDB) in infancy. ISTH Pediatric/Perinatal Subcommittee. International Society on Thrombosis and Haemostasis. *Thromb Haemost.*, 1999;81(3):456–61.
- [49] Hathaway WE. Vitamin K deficiency. *Southeast Asian J Trop Med Public Health*. 1993;24 (Suppl 1):5–9.
- [50] Nishio T, Nohara R, Aoki S, Sai HS, Izumi H, Miyoshi K, Morikawa Y, Mizuta R. Intracranial hemorrhage in infancy due to vitamin K deficiency: report of a case with multiple intracerebral hematomas with ring-like high density figures. *No To Shinkei*. 1987 Jan;39(1):65–70.
- [51] Bhat RV, Deshmukh CT. A study of Vitamin K status in children on prolonged antibiotic therapy. *Indian Pediatr*. 2003 Jan;40(1):36–40.
- [52] Sunakawa K, Akita H, Iwata S, Sato Y. Clinical superinfection and its attendant symptomatic changes in pediatrics. *Infection*. 1985;13 Suppl 1:S103–11.
- [53] De Montalembert M, Lenoir G, Saint-Raymond A, Rey J, Lefrere JJ. Increased PIVKA-II concentrations in patients with cystic fibrosis. *J Clin Pathol*. 1992 Feb;45(2):180–1.
- [54] Aydinli N, Citak A, Caliskan M, Karabocuoğlu M, Baysal S, Ozmen M. Vitamin K deficiency--late onset intracranial hemorrhage. *Eur J Paediatr Neurol* 2(4):199–203, 1998.
- [55] Chaou WT, Chou ML, Eitzman DV. Intracranial hemorrhage and vitamin K deficiency in early infancy. *J Pediatr*, 1984;105(6):880–4.

- [56] Choo KE, Tan KK, Chuah SP, Ariffin WA, Gururaj A. Haemorrhagic disease in newborn and older infants: a study in hospitalized children in Kelantan, Malaysia. *Ann Trop Paediatr.*, 1994; 14(3):231–7.
- [57] Al-Bayati MA. Analysis of causes that led to subdural bleeding, skull and rib fractures, and death in the case of baby Aerial Buie. *Medical Veritas*, 2007; 4(2):1452–69.
- [58] Al-Bayati MA. Analysis of causes that led to rib and skull fractures, sudden illness, intracranial bleeding, and death in the case of toddler Roman Pitts. *Medical Veritas*, 2008; 5 (1):1573–88.
- [59] Stys PK. Anoxic and ischemic injury of myelinated axons in CNS white matter: from mechanistic concepts to therapeutics. *J Cereb Blood Flow Metab.* 1998 Jan;18(1):2–25.
- [60] Stys PK, Waxman SG, Ransom BR. Ionic mechanisms of anoxic injury in mammalian CNS white matter: role of Na⁺ channels and Na⁽⁺⁾-Ca²⁺ exchanger. *J Neurosci.* 1992 Feb;12(2):430–9.
- [61] Dolinak D, Smith C, Graham DI. Global hypoxia per se is an unusual cause of axonal injury. *Acta Neuropathol.* 2000 Nov;100(5):553–60.
- [62] Kaur B, Ruttly GN, Timperley WR. The possible role of hypoxia in the formation of axonal bulbs. *J Clin Pathol.* 1999 Mar;52(3):203–9.
- [63] Niess C, Grauel U, Toennes SW, Bratzke H. Incidence of axonal injury in human brain tissue. *Acta Neuropathol.* 2002 Jul;104(1):79–84. Epub 2002 May 16.
- [64] Mayer SA, Lignelli A, Fink ME, Kessler DB, Thomas CE, Swarup R, Van Heertum RL. Perilesional blood flow and edema formation in acute intracerebral hemorrhage: a SPECT study. *Stroke.* 1998 Sep;29(9):1791–8.
- [65] Mehdiratta M, Kumar S, Hackney D, Schlaug G, Selim M. Association between serum ferritin level and perihematoma edema volume in patients with spontaneous intracerebral hemorrhage. *Stroke.* 2008 Apr; 39(4):1165–70. Epub 2008 Feb 21.
- [66] Krober MS, Stracener CE, Bass JW. Decreased measles antibody response after measles-mumps-rubella vaccine in infants with colds. *JAMA*, 1991; 265(16):2095–6.
- [67] Al-Bayati MA. Analysis of causes that led to Toddler Alexa Shearer's cardiac arrest and death in November 1999. *Medical Veritas*, 2004; 1(1):86–117.
- [68] Al-Bayati MA. Analysis of causes that led to baby Alan Ream Yurko's cardiac arrest and death in November of 1997. *Medical Veritas*;; 2004;1(2): 201–31.
- [69] Duclos P. Safety of immunisation and adverse events following vaccination against hepatitis B. *Expert Opin Drug Saf.* 2003 May; 2(3):225–31.
- [70] Al-Bayati MA. Analysis of causes that led to rib and skull fractures and intracranial bleeding in the case of the premature triplets Parneet, Sukhsaihaj, and Imaan. *Medical Veritas*, 2008; 5(1):1589–609.
- [71] Al-Bayati MA. Analysis of causes that led to baby Ryan's hemorrhagic pneumonia, cardiac arrest, intracranial bleeding, and retinal bleeding. *Medical Veritas*, 2008; 5(2), 1757–74.
- [72] Al-Bayati MA. Analysis of causes that led to baby Jackie Ray's developmental delay and intracranial bleeding. *Medical Veritas*, 2008; 5(2):1836–44.
- [73] Al-Bayati MA. Analysis of causes that led to the development of vitiligo in Jeanett's case with recommendations for clinical tests and treatments. *Medical Veritas*, 2007; 4(1):1251–62.
- [74] Al-Bayati MA. Severe hair loss induced by vaccines and reversed by the treatment with zinc. *Medical Veritas*, 2004; 1(2):159–62.
- [75] Zhou W, Pool V, Iskander JK, English-Bullard R, Ball R, Wise RP, Haber P, Pless RP, Mootrey G, Ellenberg SS, Braun MM, and Chen RT. Surveillance for safety after immunization: Vaccine Adverse Event Reporting System (VAERS)—United States, 1991–2001. *MMWR Surveill Summ.*, 2003;52(1):1–24.
- [76] Wise RP, Iskander J, Pratt RD, Campbell S, Ball R, Pless RP, Braun MM. Postlicensure safety surveillance for 7-valent pneumococcal conjugate vaccine. *JAMA.* 2004 Oct 13;292(14):1702–10.
- [77] Braun MM, Mootrey GT, Salive ME, Chen RT, and Ellenberg SS. Infant immunization with acellular pertussis vaccines in the United States: assessment of the first two years' data from the Vaccine Adverse Event Reporting System (VAERS). *Pediatrics*, 2000; 106(4): E51.
- [78] Niu MT, Salive ME, Ellenberg SS. Neonatal deaths after hepatitis B vaccine: the vaccine adverse event reporting system, 1991–1998. *Arch Pediatr Adolesc Med.* 1999 Dec;153(12):1279–82.
- [79] Koga K, Kawashiro N, Araki A, Watanabe M. Bilateral acute profound deafness after MMR vaccination—report of a case. *Nippon Jibiinkoka Gakkai Kaiho*, 1991; 94(8):1142–5.
- [80] Nabe-Nielsen J, Walter B. Unilateral total deafness as a complication of the measles-mumps-rubella vaccination. *Scand Audiol Suppl*, 1988; 30:69–70.
- [81] Stewart BJ, Prabhu PU. Reports of sensorineural deafness after measles, mumps, and rubella immunisation. *Arch Dis Child*; 69(1):153–4, 1993.
- [82] Miller E, Goldacre M, Pugh S, Colville A, Farrington P, Flower A, Nash J, MacFarlane L, Tettmar R. Risk of aseptic meningitis after measles, mumps, and rubella vaccine in UK children. *Lancet* ; 341(8851):979–82, 1993.
- [83] Sugiura A, Yamada A. Aseptic meningitis as a complication of mumps vaccination. *Pediatr Infect Dis J.*; 10(3):209–13, 1991.
- [84] Nakayama T, Aizawa C, Kuno-Sakai H. A clinical analysis of gelatin allergy and determination of its causal relationship to the previous administration of gelatin-containing acellular pertussis vaccine combined with diphtheria and tetanus toxoids. *J Allergy Clin Immunol.*, 1999; 103(2 Pt 1):321–5.